

Bannayan Ruvalcaba Riley Syndrome

Sashidhar V. Sagi, MD¹, Darren D. Ballard, MD¹, Rebecca A. Marks, MD², Katie R. Dunn, MS³, Charles J. Kahi, MD, MSc^{1,4}

¹Department of Medicine, Division of Gastroenterology, Indiana University School of Medicine, Indianapolis, IN

²Department of Pathology, Richard L. Roudebush Veterans Affairs Medical Center, Indianapolis, IN

³Genomic Medicine Service, Salt Lake City VAMC, Salt Lake City, UT

⁴Medicine Service, Gastroenterology Section, Richard L. Roudebush Veterans Affairs Medical Center, Indianapolis, IN

Abstract

A 63-year-old male with history of prostate cancer treated with radiation presented for a colonoscopy for small volume hematochezia. The colonoscopy revealed numerous polyps, which were found to be ganglioneuromas on histological examination. He was referred to medical genetics with suspicion for hamartomatous polyposis syndrome and was found to have a mutation in the *PTEN* gene. Based on this and suggestive clinical findings, he was diagnosed with Bannayan Ruvalcaba Riley syndrome.

Introduction

Bannayan Ruvalcaba Riley syndrome (BRRS) is an autosomal dominant hamartomatous polyposis syndrome, findings of which can include intestinal polyposis in up to 45% of patients. Polyps are predominantly in the distal ileum and colon, but any part of the GI tract may be involved. BRRS is associated with a germline mutation of the tumor suppressor gene *PTEN*, although there does not appear to be an increased incidence of colorectal cancer or other gastrointestinal cancers in patients with BRRS. We report a patient found to have BRRS following diagnostic colonoscopy.

Case Report

A 63-year-old Caucasian male presented for colonoscopy for evaluation of intermittent small volume hematochezia. He denied any abdominal or perianal pain, constipation, diarrhea, or weight loss. His past medical history was significant for a thyroidectomy 20 years ago for an unknown thyroid disorder and prostate cancer, which was diagnosed 3 years prior and treated with radiotherapy. At colonoscopy, he was noted to have multiple (>30) 1–10 mm sessile polyps throughout the entire colon, all of which were resected via snare polypectomy except those in the sigmoid colon due to the duration of the procedure (Figure 1). He also had changes consistent with radiation proctopathy, thought to be the likely source of hematochezia, and was treated with argon plasma coagulation. Histopathologic examination of the colonic polyps showed evidence of spindle cell proliferation composed of Schwann cells expanding the lamina propria and distorting the overlying colonic crypts. Within the spindled stroma, numerous ganglion cells were identified (Figure 2), suggestive of mucosal ganglioneuromas.

Given the suspicion for a hamartomatous polyposis syndrome, he was referred to the genomic medicine service. During this evaluation, the patient reported that his birth weight was over 10 pounds and he has always needed to wear extra-large hats. He also reported pigmented macules on his glans penis. There were no *café-*

ACG Case Rep J 2014;1(2):90–92. doi:10.14309/crj.2014.11. Published online: January 10, 2014.

Correspondence: Charles J. Kahi, MD, MSCR, Associate Professor of Clinical Medicine, Indiana University School of Medicine, Gastroenterology Section Chief, Roudebush VA Medical Center, 1481 W 10th Street, 111G, Indianapolis, IN 46202 (ckahi2@iupui.edu).

Copyright: © 2014 Sagi et al. This is an open-access article distributed under the terms of the Creative Commons Attribution License, which permits unrestricted use, distribution, and reproduction in any medium, provided the original author and source are credited.

au-lait spots, inguinal or axillary freckling, or cutaneous neurofibromas, to suggest neurofibromatosis. His family history was significant for a 37-year-old son with learning delays and a 4-year-old grandson with concerns for muscle weakness and autism. Neither had undergone genetic evaluation. The patient had a 67% chance of having a *PTEN* mutation based on a clinical scoring system.¹ Genetic testing demonstrated the presence of a pathogenic mutation (c.632dupG) on one copy of the *PTEN* gene. Based on clinical manifestations and the presence of the *PTEN* mutation, he was diagnosed with Bannayan Ruvalcaba Riley syndrome (BRRS). Genetic counseling of at-risk family members was also recommended.

Discussion

BRRS is an autosomal dominant hamartomatous polyposis syndrome that encompasses 3 previously described disorders including Riley-Smith syndrome, Bannayan-Zonana syndrome, and Ruvalcaba-Myhre-Smith syndrome. BRRS has an incidence of 1 in 200,000.² Patients tend to be diagnosed early in life, and manifestations may include macrocephaly, lipomatosis, hemangiomas, pigmented macules of the penis, high birth weight, proximal myopathy, joint hyperextensibility, pectus excavatum, and scoliosis, as well as developmental delay and intellectual deficiency.³ Intestinal polyposis is seen in up to 45% of patients predominantly in the distal ileum and colon, though any part of the GI tract can be involved.² Thyroid pathology findings can be benign or malignant and include multinodular goiter, follicular adenoma, or follicular and papillary carcinoma.⁴

BRRS is associated with germline mutations of the tumor suppressor gene *PTEN*, which has a significant role in the molecular pathway of cellular proliferation, migration, and apoptosis. Mutations in *PTEN* are seen in up to 65% of patients with a suspected diagnosis.^{5,6} If a mutation is confirmed, asymptomatic, at-risk first and second degree relatives should be offered genetic counseling and testing if appropriate.

There are 3 other clinically distinct syndromes associated with *PTEN* mutations, collectively referred to as *PTEN* hamartoma tumor syndrome (PHTS). These allelic disorders include Cowden syndrome, Proteus syndrome, and Proteus-like syndrome, and all have established diagnostic criteria.^{2,3} The diagnosis of Cowden syndrome can be made using either pathognomonic findings (facial trichilemmomas, acral keratosis, papillomatous papules, and mucosal lesions) or a combination of major criteria (breast cancer, thyroid cancer, macrocephaly, endometrial cancer, and Lhermitte-Duclos disease) and minor criteria (non-malignant thyroid lesions, mental retardation, hamartomatous intestinal polyps, fibrocystic breast disease, lipomas, fibromas, and genitourinary tumors or malformations). Diagnostic criteria for Proteus syndrome include malformations and hamartomatous overgrowths of multiple tissue, connective tissue nevi, and epidermal nevi, while tumors including ovarian cystadenoma, testicular tumors, central nervous system tumors, and parotid adenomas have been observed in a subset of patients. Patients with features of Proteus syndrome but not meeting diagnostic criteria are given the diagnosis of Proteus-like syndrome.

No such criteria exist for BRRS, but the syndrome is suspected in the presence of macrocephaly, hamartomatous intestinal polyposis, and pigmented macules of the glans penis in males, all of which were present in our patient. In addition, he had a presumably associated benign thyroid manifestation. In the absence of definitive diagnostic criteria for BRRS, a scoring system has been developed to assess the likelihood of a *PTEN* mutation based on the constellation of clinical findings in a patient suspected of having the condition.¹ It should be noted that some authorities feel that

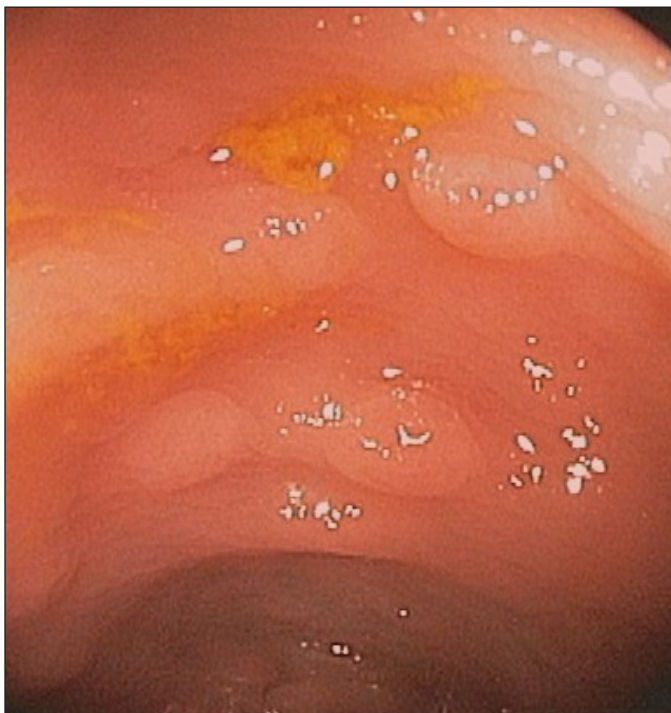

Figure 1. Endoscopic photograph of colonic polyps.

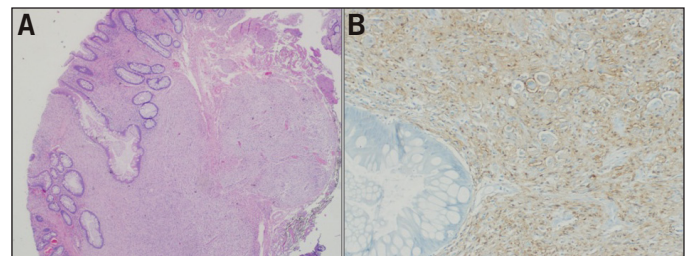


Figure 2. (A) Photomicrograph of resected polyp showing a large ganglioneuroma. (B) Immunohistochemical stain with S-100 highlighting the Schwann cells and sparing the ganglion cells.

Cowden syndrome and BRRS are varying spectrums of the same syndrome, while others feel that these are distinct entities.^{2,6}

There has been no reported increased incidence of colorectal cancer or other gastrointestinal cancers in patients with BRRS to date, though this is a rare condition with few data from large patient cohorts.⁷ Patients with BRRS should undergo screening and surveillance for gastrointestinal malignancies, including colorectal cancer, as per guidelines for average risk patients. Polyps without malignant potential (such as our patient's ganglioneuromas) do not require heightened surveillance. Patients with BRRS and *PTEN* mutations may have an undefined increased extra-intestinal cancer risk, and it has been suggested they follow the same surveillance recommendations as patients with Cowden syndrome, with screening for breast cancer, thyroid cancer, and uterine cancer.^{2,3}

Disclosures

Author contributions: SV Sagi and DD Ballard drafted the manuscript. RA Marks completed the histopathology. KR Dunn and CJ Kahi critically edited the manuscript. CJ Kahi is the article guarantor.

Financial disclosure: No support received, and no relevant disclosures.

Informed consent was obtained for this case report.

Received: June 30, 2013; Accepted: November 18, 2013.

References

1. Tan MH, Mester J, Peterson C, et al. A clinical scoring system for selection of patients for *PTEN* mutation testing is proposed on the basis of a prospective study of 3,042 probands. *Am J Hum Genet.* 2011;88(1):42–56.
2. Schreiber IR, Baker M, Amos C, et al. The hamartomatous polyposis syndromes: A clinical and molecular review. *Am J Gastroenterol.* 2005;100(2):476–90.
3. Hobert JA, Eng C. *PTEN* hamartoma tumor syndrome: An overview. *Genet Med.* 2009;11(10):687–94.
4. Laury AR, Bongiovanni M, Tille JC, et al. Thyroid pathology in *PTEN*-hamartoma tumor syndrome: Characteristic findings of a distinct entity. *Thyroid.* 2011;21:135–44.
5. Latiff ZA, Atmawidjaja RW, RajaLope RJ, et al. Bannayan Riley Ruvalcaba syndrome. *Ann Acad Med Singapore.* 2010;39(7):578–2.
6. Lachlan KL, Lucassen AM, Bunyan D, Temple IK. Cowden syndrome and Bannayan Riley Ruvalcaba syndrome represent one condition with variable expression and age-related penetrance: Results of a clinical study of *PTEN* mutation carriers. *J Med Genet.* 2007;44(9):579–85.
7. Heald B, Mester J, Rybicki L, et al. Frequent gastrointestinal polyps and colorectal adenocarcinomas in a prospective series of *PTEN* mutation carriers. *Gastroenterology.* 2010;139(6):1927–33.

Publish your work in ACG Case Reports Journal

ACG Case Reports Journal is a peer-reviewed, open-access publication that provides GI fellows, private practice clinicians, and other members of the health care team an opportunity to share interesting case reports with their peers and with leaders in the field. Visit <http://acgcasereports.gi.org> for submission guidelines. Submit your manuscript online at <http://mc.manuscriptcentral.com/acgcr>.