

# **Comparison of Dynamic Phase Enhancement of Hepatocellular Carcinoma using Gadoxetate Disodium versus Gadobenate Dimeglumine.**

## **Authors**

1. Temel Tirkes, M.D.<sup>(1)</sup>, Associate Professor of Radiology
2. Peter Mehta, M.D.<sup>(1)</sup>
3. Alex M. Aisen, M.D.<sup>(1)</sup>, Professor of Radiology
4. Chandana Lall, M.D.<sup>(1)</sup>, Professor of Radiology
5. Fatih Akisik, M.D.<sup>(1)</sup>, Associate Professor of Radiology

Indiana University School of Medicine

(1) Department of Radiology and Clinical Sciences, Indiana University School of Medicine, Indianapolis, IN, USA

(2) Department of Radiology, University of California, Irvine, Orange, CA, USA

## Corresponding author

Temel Tirkes, M.D.

Indiana University School of Medicine

Department of Radiology and Clinical Sciences

550 N. University Blvd. UH0663

Indianapolis, IN, 46202

Tel: (317) 944-1837

Fax: (317) 944-1848

[atirkes@iupui.edu](mailto:atirkes@iupui.edu)

## Disclosure

Dr. Aisen consults for Repligen, Inc, Waltham, Mass, which is developing a formulation of secretin for use in MRCP.

---

This is the author's manuscript of the article published in final edited form as:

Tirkes, T., Mehta, P., Aisen, A. M., Lall, C., & Akisik, F. (2015). Comparison of Dynamic Phase Enhancement of Hepatocellular Carcinoma Using Gadoxetate Disodium vs Gadobenate Dimeglumine: Journal of Computer Assisted Tomography, 39(4), 479–482. <http://doi.org/10.1097/RCT.0000000000000234>

1  
2  
3  
4  
5  
6  
7  
8  
9  
10  
11  
12  
13  
14  
15  
16  
17  
18  
19  
20  
21  
22  
23  
24  
25  
26  
27  
28  
29  
30  
31  
32  
33  
34  
35  
36  
37  
38  
39  
40  
41  
42  
43  
44  
45  
46  
47  
48  
49  
50  
51  
52  
53  
54  
55  
56  
57  
58  
59  
60  
61  
62  
63  
64  
65

Comparison of Dynamic Phase Enhancement of Hepatocellular  
Carcinoma using Gadoxetate Disodium versus Gadobenate  
Dimeglumine.

1  
2  
3  
4 **Abstract**  
5

6  
7  
8 **PURPOSE**  
9

10 To determine the differences in enhancement pattern of hepatocellular carcinoma (HCC)  
11 during first 5 minutes of post-contrast phases MRI with gadoxetic acid (Gd-EOB-DTPA)  
12 versus gadobenate dimeglumine (Gd-BOPTA) using the FDA approved doses.  
13  
14  
15  
16  
17  
18  
19

20 **METHODS AND MATERIALS**  
21

22 95 patients with HCC were examined on 1.5 T scanner; 74 patients with Gd-BOPTA and  
23 21 with Gd-EOB-DTPA. Using the same MRI parameters, post-contrast imaging was  
24 performed at pre-contrast, arterial, portal venous, equilibrium, and 5 minute delayed  
25 phases. Gd-EOB-DTPA was administered at a dose of 0.025 mmol/kg body weight and  
26 Gd-BOPTA at a dose of 0.1 mmol/kg body weight. Both agents were injected at rate of 2  
27 mL/sec and arterial phase was timed by using bolus-triggering software. The contrast-to-  
28 noise ratio (CNR) was calculated by  $(SI_{\text{lesion}} - SI_{\text{liver}})/SD_{\text{background}}$ . (SD=Standard  
29 Deviation, SI=signal intensity)  
30  
31  
32  
33  
34  
35  
36  
37  
38  
39  
40  
41  
42  
43

44 **RESULTS**  
45

46 Mean CNRs were not statistically significant different in arterial (p=0.3), portal venous  
47 (p=0.1) and 5 minute delayed phases (p=0.73). CNR of lesions scanned with Gd-EOB-  
48 DTPA was significantly higher in the equilibrium phase (p=0.006). When pooling the  
49 data from all for post-contrast phases, HCCs demonstrated no significant change in  
50 enhancement pattern with Gd-EOB-DTPA compared to Gd-BOPTA. CNRs of lesions  
51  
52  
53  
54  
55  
56  
57  
58  
59  
60  
61

1  
2  
3  
4  
5  
6  
7  
8  
9  
10  
11  
12  
13  
14  
15  
16  
17  
18  
19  
20  
21  
22  
23  
24  
25  
26  
27  
28  
29  
30  
31  
32  
33  
34  
35  
36  
37  
38  
39  
40  
41  
42  
43  
44  
45  
46  
47  
48  
49  
50  
51  
52  
53  
54  
55  
56  
57  
58  
59  
60  
61  
62  
63  
64  
65

scanned with Gd-EOB-DTPA were lower in arterial phase compared to Gd-BOPTA, though this did not reach statistical significance.

## CONCLUSION

Gd-EOB-DTPA in HCC imaging resulted in lower CNR during the arterial phase and higher CNR during the portal venous, equilibrium and 5 minute delayed phases compared to Gd-BOPTA using the FDA approved doses, however overall there was no statistical significance (P=0.077).

1  
2  
3  
4  
5  
6  
7  
8  
9  
10  
11  
12  
13  
14  
15  
16  
17  
18  
19  
20  
21  
22  
23  
24  
25  
26  
27  
28  
29  
30  
31  
32  
33  
34  
35  
36  
37  
38  
39  
40  
41  
42  
43  
44  
45  
46  
47  
48  
49  
50  
51  
52  
53  
54  
55  
56  
57  
58  
59  
60  
61  
62  
63  
64  
65

**Keywords:** Hepatocellular carcinoma, MRI, contrast, Gadoxetate Disodium, Gadobenate

Dimeglumine

1  
2  
3  
4 **Introduction**  
5  
6  
7  
8

9 Gadoxetate Isodium (Gd-EOB-DTPA, Eovist/Primovist®, Bayer) was approved by the  
10 FDA for clinical use in 2008 and has emerged as a valuable hepatobiliary phase MRI  
11 contrast agent [1,2]. The presence or absence of contrast enhancement in the  
12 hepatobiliary phase can be very useful in differentiating previously indeterminate hepatic  
13 lesions, such as focal nodular hyperplasia, well-differentiated hepatocellular carcinoma  
14 (HCC), adenomas, atypical hemangiomas, and metastases [2-4].  
15  
16  
17  
18  
19  
20  
21  
22  
23  
24  
25

26 Approximately 50% of Gd-EOB-DTPA undergoes hepatobiliary excretion and 50% is  
27 excreted by the kidneys [2]. After being taken up by hepatocytes via the organic anion  
28 transport protein, Gd-EOB-DTPA redistributes to the extracellular space and undergoes  
29 delayed excretion into bile ducts or sinusoids [5]. Extracellular space redistribution and  
30 gradual hepatobiliary phase excretion allows for prolonged dynamic imaging and a  
31 progressive increase in enhancement of hepatocytes and hepatocyte-containing lesions.  
32  
33  
34  
35  
36  
37  
38  
39  
40  
41  
42  
43  
44  
45  
46  
47  
48  
49  
50  
51  
52  
53  
54  
55  
56  
57  
58  
59  
60  
61  
62  
63  
64  
65

When hepatocellular dysfunction is present, as a result of advanced cirrhosis, Gd-EOB-DTPA is increasingly excreted via the alternate renal pathway [6], which may reduce visibility of lesions on the hepatobiliary phase images. In comparison, Gadobenate dimeglumine (Gd-BOPTA) undergoes 78-96% renal excretion and therefore yields a lower percentage of hepatocyte enhancement in the hepatobiliary phase when compared to Gd-EOB-DTPA [7].

1  
2  
3  
4 In practical terms, the hepatobiliary phase of scans performed with Gd-EOB-DTPA often  
5 provides valuable diagnostic information; for example, most HCC's and almost all  
6 metastatic lesions do not take up the agent, and will therefore appear as low signal focal  
7 lesions on 20-minute delayed hepatobiliary phase images [2].  
8  
9

10  
11  
12  
13  
14  
15  
16 There is, however, a possible disadvantage of Gd-EOB-DTPA. Gd-EOB-DTPA is  
17 distributed at a molar concentration less than half that of most other agents, including Gd-  
18 BOPTA, and the label instructions recommends a lower milliliter dose (Table 1). Thus,  
19 the total number of moles of agent is usually 25% of a typical scan performed with Gd-  
20 BOPTA. Since arterial phase wash-in and delayed phase relative wash-out are hallmarks  
21 of HCC diagnosis, this can be an issue in interpreting Gd-EOB-DTPA enhanced MR  
22 scans. For this reason, we investigated and compared the enhancement of HCC with Gd-  
23 EOB-DTPA to that of Gd-BOPTA within the first 5 minutes of contrast injection.  
24  
25  
26  
27  
28  
29  
30  
31  
32  
33  
34  
35  
36  
37

### 38 **Materials and Methods**

39  
40  
41  
42  
43 Following FDA approval of Gd-EOB-DTPA in 2008, our institution, a major academic  
44 tertiary care center with a large liver transplant service, started using Gd-EOB-DTPA for  
45 screening and follow up of HCC in all liver MR exams over a period of 9 months.  
46  
47

48 Patients had chronic liver disease and were scanned on 1.5 T MR scanners (Magnetom  
49 Avanto, Siemens Medical Solutions, Malvern, PA USA). Following approval from the  
50 institutional review board, a HIPPA compliant retrospective study was performed. Data  
51 collection was performed in patients with known HCC that were scanned during this 9-  
52  
53  
54  
55  
56  
57  
58  
59  
60  
61

1  
2  
3  
4 month time period with Gd-EOB-DTPA (n=21 patients) and from prior cases of known  
5  
6 HCC scanned with Gd-BOPTA (n=78).  
7  
8  
9

10  
11 In both groups, same imaging parameters were used to acquire contrast-enhanced phases  
12  
13 using a 3D fat-suppressed, T1-weighted volume interpolated gradient echo sequence  
14  
15 (VIBE<sup>®</sup>, Siemens Medical Solutions, Malvern, PA, USA) (TR: 4.98 ms, TE: 2.27 ms, flip  
16  
17 angle:12). FDA approved and manufacturer recommended dose of 0.025 mmol/kg for  
18  
19 Gd-EOB-DTPA and 0.1 mmol/kg for Gd-BOPTA were administered intravenously at a  
20  
21 rate of 2 ml/sec, followed by a 20 mL normal saline flush. Bolus triggering software was  
22  
23 utilized to time the arterial phase scans in both groups. Timing of the arterial phase was  
24  
25 approximately 20 seconds, portal venous phase 50 seconds, equilibrium phase 120  
26  
27 seconds and delayed phase 5 minutes after contrast injection. Patients imaged with Gd-  
28  
29 EOB-DTPA were additionally imaged at 10 and 20 minutes but these time points are  
30  
31 excluded from comparison. K-space was acquired in a linear fashion.  
32  
33  
34  
35  
36  
37  
38  
39  
40

41 The degree of enhancement of liver lesions was quantified by drawing a circular region  
42  
43 of interest (ROI) within the lesion margin ( $SI_{\text{lesion}}$ ) and around normal liver parenchyma  
44  
45 ( $SI_{\text{liver}}$ ). The sensitivity of HCC detection with Gd-EOB-DTPA is decreased in lesions  
46  
47 less than 10 mm in diameter [8]; therefore minimum ROI was set at  $1 \text{ cm}^2$ . The standard  
48  
49 deviation of background noise was calculated by drawing an ROI outside of the patient  
50  
51 ( $SD_{\text{background}}$ ) on the same image. The contrast-to-noise ratio (CNR) was calculated using  
52  
53 the equation:  $CNR = (SI_{\text{lesion}} - SI_{\text{liver}}) / SD_{\text{background}}$ .  
54  
55  
56  
57  
58  
59  
60  
61



1  
2  
3  
4 *Statistical Analysis*  
5

6 The Mixed-Effect Repeat Measure (MMRM) model with unstructured variance-  
7 covariance matrix was used to model the repeated CNR including time, group (Gd-  
8 BOPTA or Gd-EOB-DTPA), and the interaction between time and group as fixed effects.  
9  
10 The F tests were used to examine the overall difference between the two groups and the  
11 difference in mean CNR between the Gd-EOB-DTPA and Gd-BOPTA group at each  
12 time point.  
13  
14  
15  
16  
17  
18  
19  
20  
21  
22

23 **Results**  
24

25  
26 Mean CNRs after administration of Gd-EOB-DTPA and Gd-BOPTA are shown on  
27 Figure 1 and Table 2. In the post contrast arterial phase, the mean CNR was 9.7 ( $\pm 49$ ) in  
28 the Gd-EOB-DTPA group and 19 ( $\pm 36$ ) in the Gd-BOPTA group. In the portal venous  
29 phase, the mean CNR was -15.2 ( $\pm 38$ ) in the Gd-EOB-DTPA group and 4.3 ( $\pm 55$ ) in the  
30 Gd-BOPTA group. In the equilibrium phase, the mean CNR was -25 ( $\pm 34$ ) in the Gd-  
31 EOB-DTPA group and -2.9 ( $\pm 28$ ) in the gadobenate group. In the 5 minute delayed  
32 phase, the mean CNR was -31.4 ( $\pm 45$ ) in the Gd-EOB-DTPA group and -27.7 ( $\pm 35$ ) in  
33 the Gd-BOPTA group.  
34  
35  
36  
37  
38  
39  
40  
41  
42  
43  
44  
45  
46  
47

48 The overall difference in CNRs when including all time points did not reach statistical  
49 significance ( $P=0.077$ ). There was greater arterial enhancement on the arterial phase  
50 images with Gd-BOPTA than with Gd-EOB-DTPA, but this did not reach statistical  
51 significance. However, the contrast reverses on later vascular phase images; lesions are  
52 usually hypointense compared to liver on later vascular phases with both agents, a  
53  
54  
55  
56  
57  
58  
59  
60  
61

1  
2  
3  
4 phenomenon termed “washout” and indicated by negative CNR values. Our data showed  
5  
6 greater CNRs and seemingly greater lesion “washout” relative to liver on the later  
7  
8 vascular phases on the Gd-EOB-DTPA images compared to the Gd-BOPTA. This  
9  
10 difference may be because of progressive enhancement of the liver with Gd-EOB-DTPA,  
11  
12 likely due to the combined effects of vascular perfusion and hepatocyte uptake of the  
13  
14 contrast agent (Figure 2). Negative CNRs observed beginning with portal venous phase  
15  
16 using Gd-EOB-DTPA, compared to equilibrium phase with the Gd-BOPTA.  
17  
18  
19  
20  
21  
22

## 23 **Discussion**

24  
25  
26  
27  
28  
29 When compared to Gd-BOPTA, at standard doses Gd-EOB-DTPA demonstrates lower  
30  
31 enhancement in normal vasculature and solid abdominal organs [9] and lower dynamic  
32  
33 enhancement of the liver vasculature [10]. Frydrychowicz et al compared dynamic post  
34  
35 contrast hepatic vasculature signal to noise ratio (SNR) with the higher (non-FDA  
36  
37 approved) Gd-EOB-DTPA dose of 0.05 mmol/kg to the standard dose of Gd-BOPTA.  
38  
39 Hepatic vascular SNR was lower in the Gd-EOB-DTPA group despite doubling the FDA-  
40  
41 approved dose, and it was suggested that this agent be reserved for cases in which  
42  
43 hepatobiliary phase imaging is needed [7]. Therefore, it should not be surprising that a  
44  
45 hypervascular lesion such as HCC should show relatively lower early dynamic  
46  
47 enhancement with Gd-EOB-DTPA compared to Gd-BOPTA.  
48  
49  
50  
51  
52  
53  
54  
55

56 The sentinel paper by Vogl et al comparing the contrast enhancement in liver tumors with  
57  
58 Gd-EOB-DTPA versus Gd-BOPTA was published in 1996 [11]. Patients with a variety  
59  
60  
61

1  
2  
3  
4 of known liver lesions, including HCC (not all had cirrhosis), focal nodular hyperplasia  
5  
6 (FNH), hemangioma, and metastatic disease were scanned with dynamic post contrast  
7  
8 T1-weighted FLASH imaging (TR/TE=154/6, 70 degree flip angle, NEX=1) with  
9  
10 different doses of Gd-EOB-DTPA (0.0125, 0.025, and 0.05 mmol/kg). Within 1 week,  
11  
12 the same patients were scanned using the same dynamic MR pulse sequences with the  
13  
14 standard dose of Gd-BOPTA (0.1 mmol/kg). The study included 12 patients with known  
15  
16 HCC. Of these 12 patients, 4 were given the highest (0.05 mmol/kg) dose of Gd-EOB-  
17  
18 DTPA, only 5 were given the (now FDA-approved) intermediate dose (0.025 mmol/kg),  
19  
20 and 3 were given the lowest dose (0.0125 mmol/kg). It should be noted that the first post-  
21  
22 contrast image on this study was acquired at 45 seconds following contrast injection  
23  
24 which is past the arterial phase and close to the portal venous phase using modern day  
25  
26 scanners. The lesions in the 5 patients given the intermediate dose of Gd-EOB-DTPA  
27  
28 showed 45 second “wash-in” of contrast media, with subsequent progressive “wash-out”  
29  
30 of contrast media throughout the portal venous, equilibrium, delayed, and hepatobiliary  
31  
32 phases. When later scanned with Gd-BOPTA, these lesions showed similar characteristic  
33  
34 dynamic “wash-in” and “wash-out” of contrast during the first 5 minutes after contrast  
35  
36 administration. However, the measured percentage of contrast enhancement of HCC (SI  
37  
38 postcontrast – SI precontrast) / SI precontrast in the Gd-BOPTA group was  
39  
40 approximately 20-25% higher at all time points in the first 5 minutes when compared to  
41  
42 Gd-EOB-DTPA. By ignoring the first 3 minutes of contrast enhancement, the authors  
43  
44 concluded that the dynamic enhancement characteristics of HCC with the 0.025 mmol/kg  
45  
46 and 0.05 mmol/kg doses of Gd-EOB-DTPA were “similar at 3 minutes” to the 0.1  
47  
48 mmol/kg dose of Gd-BOPTA. Another remote study by Reimer et al published in 1996  
49  
50  
51  
52  
53  
54  
55  
56  
57  
58  
59  
60  
61

1  
2  
3  
4 concluded that a dose of 0.0125 mmol/kg was sufficient for the detection of liver lesions  
5  
6 with significant improvement of lesion detection at 20 and 45 minutes [12]. Conclusions  
7  
8 from these studies may have weighed in the FDA decision to focus on the hepatobiliary  
9  
10 phase imaging with Gd-EOB-DTPA and approve the intermediate (0.025 mmol/kg) Gd-  
11  
12 EOB-DTPA dose for clinical use in 2008.  
13  
14

15  
16  
17  
18  
19 Our current study has the advantage of a much larger sample size of HCC lesions in the  
20  
21 Gd-EOB-DTPA group (n=21) and Gd-BOPTA group (n=74), versus a total sample size  
22  
23 of 12 in the 1996 study. However, our study involved retrospective analysis of HCC  
24  
25 lesions in different patients, while the 1996 study evaluated known lesions in the same  
26  
27 patient with both contrast agents. The relatively small, disproportionate sample size of  
28  
29 patients in the Gd-EOB-DTPA group (n=21) may have limited statistical analysis.  
30  
31  
32

33  
34  
35  
36 The preponderance of evidence in our study and in the literature suggests that Gd-EOB-  
37  
38 DTPA offers relatively lower CNR in the liver vasculature, parenchyma, and  
39  
40 hepatocellular carcinomas during the first 5 minutes of dynamic imaging when compared  
41  
42 to Gd-BOPTA. Given the identical imaging parameters, decreased arterial phase CNRs in  
43  
44 the Gd-EOB-DTPA group in our study is probably secondary to using the lower FDA  
45  
46 approved and manufacturer recommended dose of Gd-EOB-DTPA (0.025 mmol/kg)  
47  
48 which is 25% of the dose administered by Gd-BOPTA (0.1 mmol/kg). Our clinical  
49  
50 experiences combined with relatively higher cost of Gd-EOB-DTPA have led our  
51  
52 institution to stop using the use of Gd-EOB-DTPA for screening of HCC in suspected  
53  
54 patients. It remains a useful agent for problem solving in cirrhotic patients, and other  
55  
56  
57  
58  
59  
60  
61

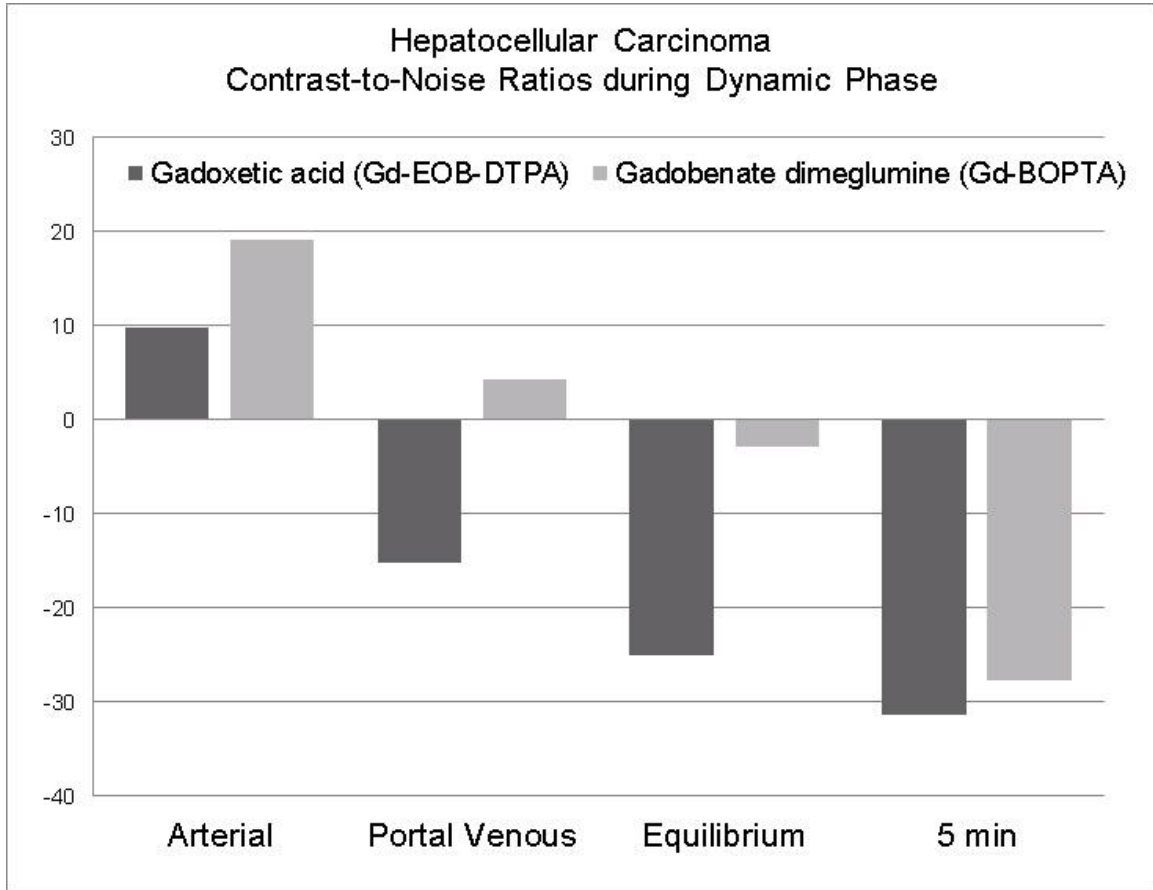
1  
2  
3  
4 lesions such as metastasis, for which the lower arterial phase enhancement may be less of  
5  
6 an issue, and for whom the hepatobiliary phase images may be especially efficacious.  
7  
8  
9

## 10 11 **Conclusion**

12  
13  
14 Using the FDA approved doses of the two contrast agents, Gd-EOB-DTPA yields a lower  
15  
16 but not statistically significant CNR for HCC compared to Gd-BOPTA during the arterial  
17  
18 phase. Average CNR was higher with Gd-EOB-DTPA during portal venous and 5 minute  
19  
20 delayed phases and this advantage is probably secondary to progressive enhancement  
21  
22 within the liver parenchyma. The overall difference in CNRs including all time points did  
23  
24 not reach statistical significance (P=0.077).  
25  
26  
27  
28  
29  
30  
31  
32  
33  
34  
35  
36  
37  
38  
39  
40  
41  
42  
43  
44  
45  
46  
47  
48  
49  
50  
51  
52  
53  
54  
55  
56  
57  
58  
59  
60  
61  
62  
63  
64  
65

1  
2  
3  
4 **Figures**  
5

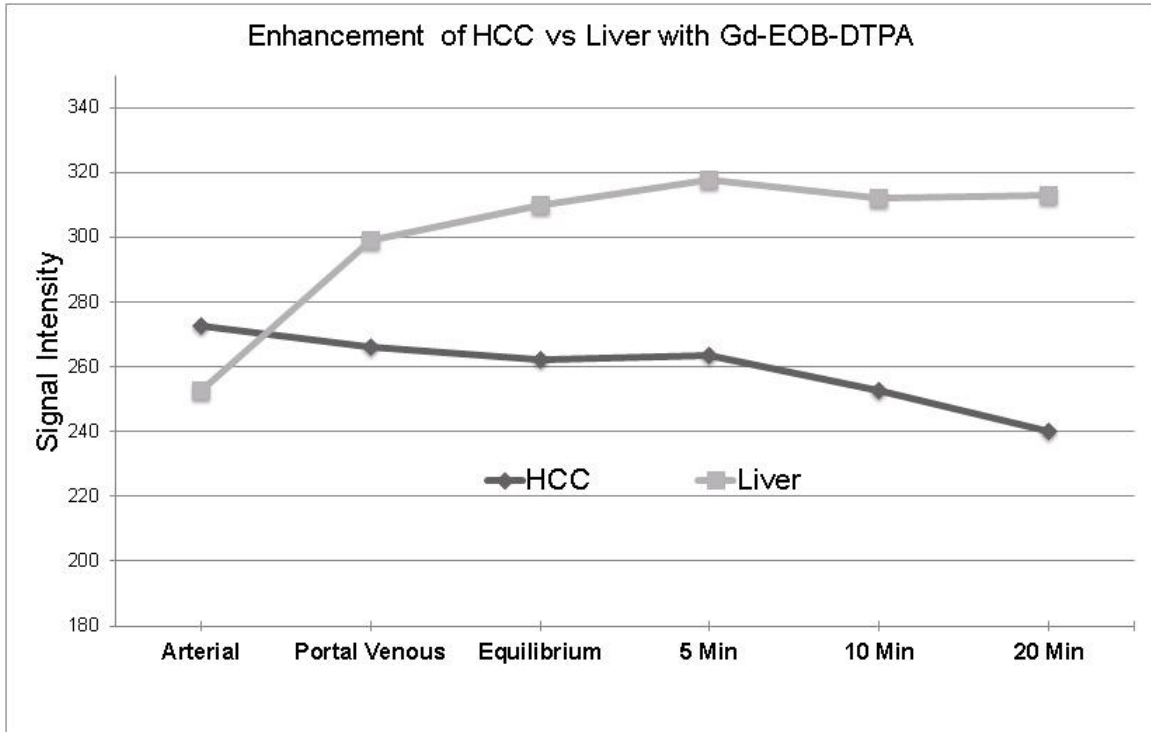
6  
7 **Figure 1.** Comparison of the CNRs during the first 5 minutes with Gd-EOB-DTPA  
8  
9 versus Gd-BOPTA.  
10



42  
43  
44  
45  
46  
47  
48  
49  
50  
51  
52  
53  
54  
55  
56  
57  
58  
59  
60  
61  
62  
63  
64  
65

Bar plot of least square mean of the Gd-EOB-DTPA and Gd-BOPTA group at each time point. Mean CNR of HCC lesions in the arterial (20 sec), portal venous (50 sec), equilibrium (120 secs), and 5 minute delayed post contrast sequences. Gd-BOPTA yields approximately twice the CNR of Gd-EOB-DTPA during the arterial phase. Gd-EOB-DTPA shows washout earlier than the Gd-BOPTA, beginning with the portal venous phase.  $CNR = (SI_{\text{lesion}} - SI_{\text{liver}}) / SD_{\text{background}}$ .

**Figure 2.** Comparison of enhancement curves of HCC and liver with GD-EOB-DTPA.



Linear plot chart of average signal intensity curves of HCC and liver parenchyma at all time points. There is progressive enhancement of the liver with Gd-EOB-DTPA, likely due to hepatocyte uptake of the contrast agent. HCC shows higher signal intensity compared to the liver parenchyma during the arterial phase and rapidly starts losing its signal intensity over 20 minutes. Progressive enhancement of the liver parenchyma compared to the HCC is probably one of the reasons of relatively higher CNRs during the portal venous, equilibrium and 5 minute delayed phases of the GD-EOB-DTPA.

1  
2  
3  
4 **Tables**  
5  
6

7 **Table 1.** Comparison of Gd-EOB-DTPA and Gd-BOPTA dosage based on FDA and  
8  
9 manufacturer recommendations.  
10

11  
12  
13  
14  
15  
16  
17  
18  
19  
20  
21  
22  
23  
24  
25  
26  
27

<b>Contrast agent</b>	<b>Concentration</b>	<b>FDA recommended dose</b>
<b>Gd-EOB-DTPA</b>	181 mg/ml	0.025 mmol/kg
<b>Gd-BOPTA</b>	529 mg/ml	0.1 mmol/kg

28  
29  
30 **Table 2.** Comparison of mean CNR in Gd-EOB-DTPA and Gd-BOPTA groups at the  
31  
32 arterial, portal venous, equilibrium, and 5 minute delayed time points.  
33

34  
35  
36  
37  
38  
39  
40  
41  
42  
43  
44  
45  
46  
47  
48  
49  
50  
51  
52  
53  
54  
55  
56  
57  
58  
59  
60  
61

	<b>CNR Gd-EOB-DTPA</b>	<b>CNR Gd-BOPTA</b>	<b>Least Square Mean Difference</b>	<b>P value</b>
Arterial	9.7 ± 49	19.5 ± 36	-9.8	0.3
Portal Venous	-16.3 ± 38	4.3 ± 55	-20.6	0.1
Equilibrium	-25 ± 34	-4.2 ± 28	-20.9	0.006
5 min Delayed	-31.4 ± 45	-28.2 ± 35	-3.1	0.73
Overall CNR difference including all time points				0.08

62  
63  
64  
65



1  
2  
3  
4  
5  
6  
7  
8  
9  
10  
11  
12  
13  
14  
15  
16  
17  
18  
19  
20  
21  
22  
23  
24  
25  
26  
27  
28  
29  
30  
31  
32  
33  
34  
35  
36  
37  
38  
39  
40  
41  
42  
43  
44  
45  
46  
47  
48  
49  
50  
51  
52  
53  
54  
55  
56  
57  
58  
59  
60  
61  
62  
63  
64  
65

CNR data are expressed as mean  $\pm$  SD. Only statistically significant difference in CNRs of two groups was during equilibrium phase ( $p=0.006$ ). When including all time points, there was no statistical significance ( $p=0.08$ ).

## References

1. Chou CT, Chen YL, Su WW, Wu HK, Chen RC (2010) Characterization of cirrhotic nodules with gadoxetic acid-enhanced magnetic resonance imaging: the efficacy of hepatocyte-phase imaging. *Journal of magnetic resonance imaging* : JMRI 32 (4):895-902. doi:10.1002/jmri.22316
2. Ringe KI, Husarik DB, Sirlin CB, Merkle EM (2010) Gadoxetate disodium-enhanced MRI of the liver: part 1, protocol optimization and lesion appearance in the noncirrhotic liver. *AJR American journal of roentgenology* 195 (1):13-28. doi:10.2214/AJR.10.4392
3. Halavaara J, Breuer J, Ayuso C, Balzer T, Bellin MF, Blomqvist L, Carter R, Grazioli L, Hammerstingl R, Huppertz A, Jung G, Krause D, Laghi A, Leen E, Lupatelli L, Marsili L, Martin J, Pretorius ES, Reinhold C, Stiskal M, Stolpen AH (2006) Liver tumor characterization: comparison between liver-specific gadoxetic acid disodium-enhanced MRI and biphasic CT--a multicenter trial. *Journal of computer assisted tomography* 30 (3):345-354
4. Huppertz A, Haraida S, Kraus A, Zech CJ, Scheidler J, Breuer J, Helmberger TK, Reiser MF (2005) Enhancement of focal liver lesions at gadoxetic acid-enhanced MR imaging: correlation with histopathologic findings and spiral CT--initial observations. *Radiology* 234 (2):468-478. doi:10.1148/radiol.2342040278
5. Nassif A, Jia J, Keiser M, Oswald S, Modess C, Nagel S, Weitschies W, Hosten N, Siegmund W, Kuhn JP (2012) Visualization of hepatic uptake transporter function in healthy subjects by using gadoxetic acid-enhanced MR imaging. *Radiology* 264 (3):741-750. doi:10.1148/radiol.12112061
6. Katsube T, Okada M, Kumano S, Hori M, Imaoka I, Ishii K, Kudo M, Kitagaki H, Murakami T (2011) Estimation of liver function using T1 mapping on Gd-EOB-DTPA-enhanced magnetic resonance imaging. *Investigative radiology* 46 (4):277-283. doi:10.1097/RLI.0b013e318200f67d
7. Frydrychowicz A, Nagle SK, D'Souza SL, Vigen KK, Reeder SB (2011) Optimized high-resolution contrast-enhanced hepatobiliary imaging at 3 tesla: a cross-over comparison of gadobenate dimeglumine and gadoxetic acid. *Journal of magnetic resonance imaging* : JMRI 34 (3):585-594. doi:10.1002/jmri.22713
8. Liu X, Zou L, Liu F, Zhou Y, Song B (2013) Gadoxetic acid disodium-enhanced magnetic resonance imaging for the detection of hepatocellular carcinoma: a meta-analysis. *PloS one* 8 (8):e70896. doi:10.1371/journal.pone.0070896
9. Tamada T, Ito K, Sone T, Yamamoto A, Yoshida K, Kakuba K, Tanimoto D, Higashi H, Yamashita T (2009) Dynamic contrast-enhanced magnetic resonance imaging of abdominal solid organ and major vessel: comparison of enhancement effect between Gd-EOB-DTPA and Gd-DTPA. *Journal of magnetic resonance imaging* : JMRI 29 (3):636-640. doi:10.1002/jmri.21689
10. Brismar TB, Dahlstrom N, Edsberg N, Persson A, Smedby O, Albiin N (2009) Liver vessel enhancement by Gd-BOPTA and Gd-EOB-DTPA: a comparison in healthy volunteers. *Acta radiologica* 50 (7):709-715. doi:10.1080/02841850903055603
11. Vogl TJ, Kummel S, Hammerstingl R, Schellenbeck M, Schumacher G, Balzer T, Schwarz W, Muller PK, Bechstein WO, Mack MG, Sollner O, Felix R (1996) Liver tumors: comparison of MR imaging with Gd-EOB-DTPA and Gd-DTPA. *Radiology* 200 (1):59-67. doi:10.1148/radiology.200.1.8657946

1  
2  
3  
4  
5  
6  
7  
8  
9  
10  
11  
12  
13  
14  
15  
16  
17  
18  
19  
20  
21  
22  
23  
24  
25  
26  
27  
28  
29  
30  
31  
32  
33  
34  
35  
36  
37  
38  
39  
40  
41  
42  
43  
44  
45  
46  
47  
48  
49  
50  
51  
52  
53  
54  
55  
56  
57  
58  
59  
60  
61  
62  
63  
64  
65

12. Reimer P, Rummeny EJ, Shamsi K, Balzer T, Daldrup HE, Tombach B, Hesse T, Berns T, Peters PE (1996) Phase II clinical evaluation of Gd-EOB-DTPA: dose, safety aspects, and pulse sequence. *Radiology* 199 (1):177-183.  
doi:10.1148/radiology.199.1.8633143

Figure 1

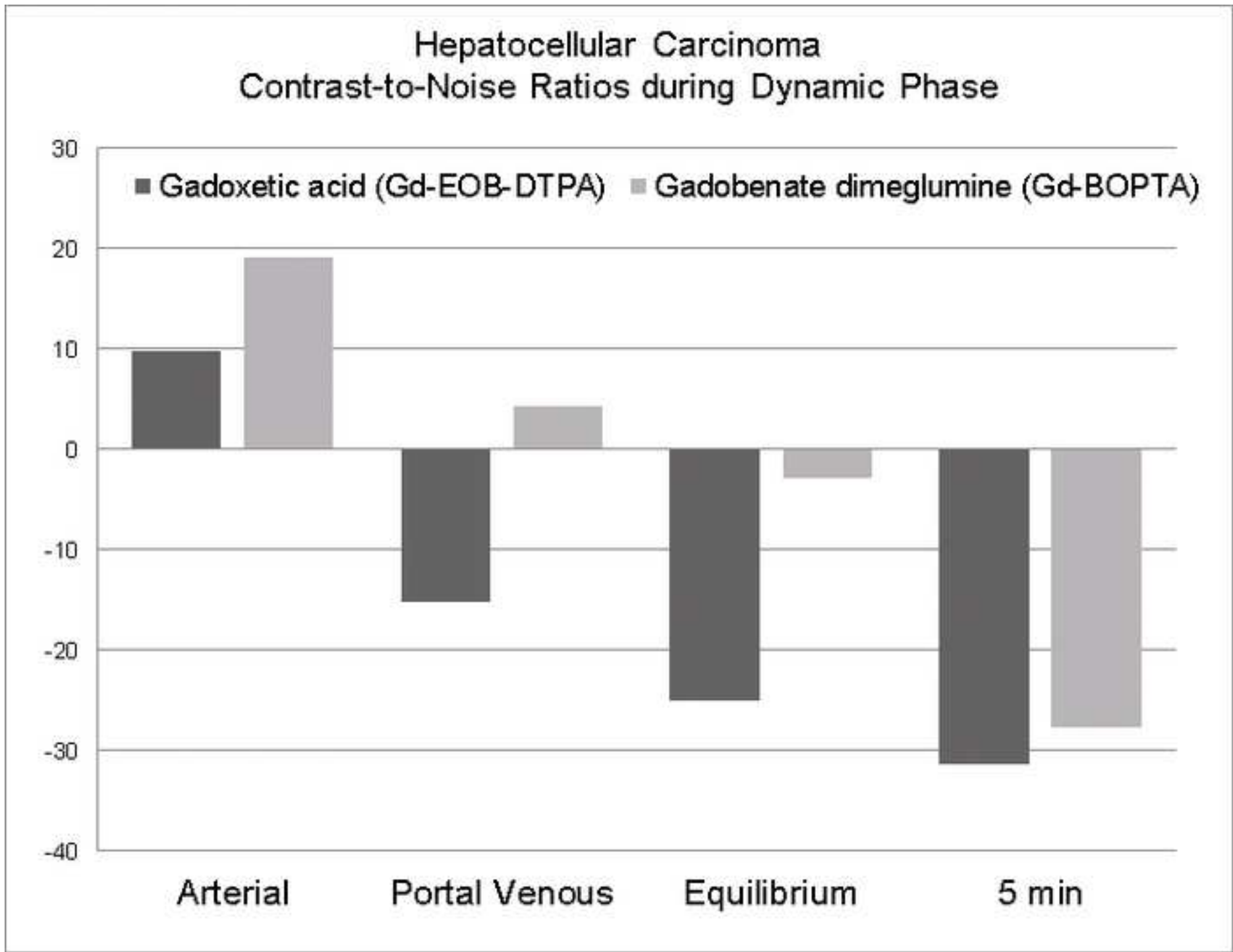


Figure 2

