

Oral Lichen Planus: Clinical Presentation and Management

(Lichen plan : présentation clinique et prise en charge)

• Paul C. Edwards, BSc, MSc, DDS •
• Robert Kelsch, DMD •

S o m m a i r e

Le lichen plan est une affection chronique de la muqueuse qui s'observe fréquemment en cabinet. Le lichen plan serait le résultat d'une réaction immunitaire anormale au cours de laquelle les cellules épithéliales seraient perçues comme des corps étrangers à la suite de changements dans l'antigénicité de la surface cellulaire. Cette affection se présente sous diverses manifestations buccales. La forme réticulaire est la plus répandue mais les formes érosive et atrophique, bien que moins courantes, sont les plus susceptibles de causer des symptômes. Le traitement consiste essentiellement en l'application de corticostéroïdes topiques sur les lésions symptomatiques. Les lésions résistantes peuvent être traitées au moyen de stéroïdes systémiques ou autres médicaments à action générale. Cependant, les données démontrant la supériorité de ces traitements au placebo sont peu concluantes. Enfin, comme des rapports font état d'un risque légèrement supérieur de développer un épithélioma spinocellulaire dans les zones présentant des lésions érosives, il est important que le clinicien soit attentif à toute lésion lichéniforme intra-buccale et il est recommandé de faire un suivi périodique de tous les patients souffrant de lichen plan.

Mots clés MeSH : lichen planus, oral/diagnosis; lichen planus, oral/therapy; precancerous conditions/pathology

© J Can Dent Assoc 2002; 68(8):494-9
Cet article a été révisé par des pairs.

Lichen planus is a relatively common disorder, estimated to affect 0.5% to 2.0% of the general population.¹ It is a chronic, inflammatory disease that affects mucosal and cutaneous tissues. Oral lichen planus (OLP) occurs more frequently than the cutaneous form and tends to be more persistent and more resistant to treatment.²

In view of the prevalence of OLP and the potential of this chronic disease to cause significant discomfort, it is important for clinicians to be aware of its clinical presentation and management.

Etiology and Pathogenesis

Lichen planus is believed to result from an abnormal T-cell-mediated immune response in which basal epithelial cells are recognized as foreign because of changes in the antigenicity of their cell surface.³ The cause of this immune-mediated basal cell damage is unknown. Likewise, it is unknown if lichen planus represents a single disease process or several closely related entities with similar clinical presentations. A recent immunologic comparison of 2 variants of OLP

suggested that different immunopathogenic mechanisms might be involved.⁴

Clinical Presentation

Lichen planus affects primarily middle-aged adults, and the prevalence is greater among women.⁵ Children are only rarely affected.⁶ The classic skin lesions of the cutaneous form of lichen planus can be described as purplish, polygonal, planar, pruritic papules and plaques.⁷ These skin lesions commonly involve the flexor surfaces of the legs and arms, especially the wrists (Fig. 1). The nail beds may also be affected, with resultant ridging, thinning and subungual hyperkeratosis.⁷ Scalp involvement, if untreated, can lead to scarring and permanent hair loss.

Since 30% to 50% of patients with oral lesions also have cutaneous lesions, the presence of these characteristic cutaneous lesions can aid in the diagnosis of OLP.

Several types of OLP have been described, the 2 main types being reticular and erosive OLP.² It is not uncommon for the same patient to present with multiple forms of OLP.

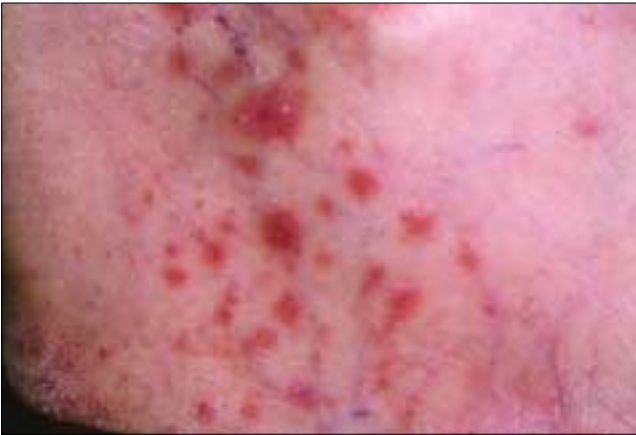

Figure 1: Cutaneous lichen planus on the flexor surface of the wrist. The condition presents as purple, polygonal, plaque-like lesions.

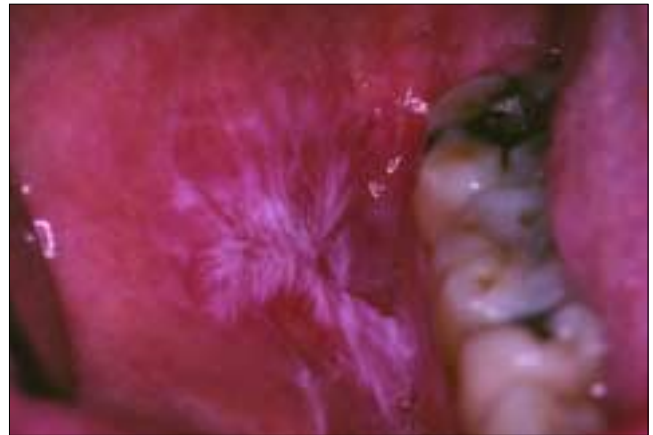

Figure 2: Reticular oral lichen planus involving the buccal mucosa. Numerous interlacing white keratotic lines are evident.

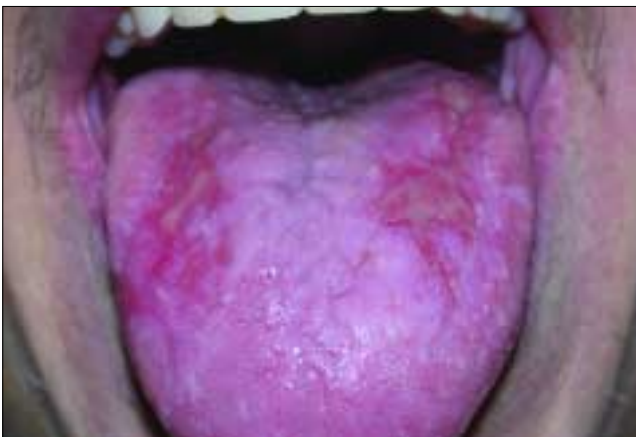

Figure 3: Plaque-type variant of reticular oral lichen planus with erosive areas involving the dorsum of the tongue.

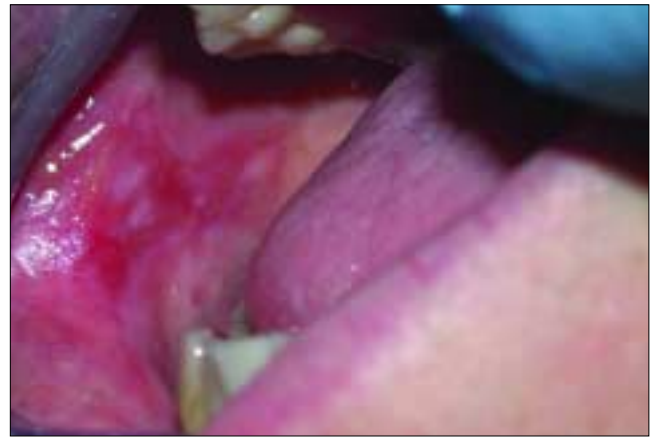

Figure 4: Erosive oral lichen planus involving the buccal mucosa. The condition is characterized by erythematous areas and interspersed pseudomembranous areas.

Reticular OLP

The reticular form is the most common type of OLP. It presents as interlacing white keratotic lines (known as Wickham's striae) with an erythematous border (Fig. 2). The striae are typically located bilaterally on the buccal mucosa, mucobuccal fold, gingiva and, less commonly, the tongue, palate and lips.

A variant of reticular OLP is the plaque-like form, which clinically resembles leukoplakia but which has a multifocal distribution. These plaque-like lesions can range in presentation from smooth, flat areas to irregular, elevated areas. This variant is commonly found on the dorsum of the tongue (Fig. 3) and on the buccal mucosa.

Both the reticular form and its plaque-like variant are usually asymptomatic.

Erosive OLP

Erosive OLP is the second most common type. It presents as a mix of erythematous and ulcerated areas surrounded by finely radiating keratotic striae (Figs. 4 and 5). When erosive OLP involves the attached gingival tissue, it is called desqua-

mative gingivitis. The lesions of erosive OLP migrate over time and tend to be multifocal. Patients with this form of OLP often present with symptoms ranging from episodic pain to severe discomfort that can interfere with normal masticatory function.

Two additional presentations are the atrophic and bullous forms, which are considered variants of the erosive type. Atrophic OLP appears as diffuse, erythematous patches surrounded by fine white striae. This form can cause significant discomfort. In the bullous form, intraoral bullae are present on the buccal mucosa and the lateral borders of the tongue; the bullae rupture soon after they appear, which results in the classic appearance of erosive OLP.¹

Differential Diagnosis

The diagnosis of OLP can be rendered more confidently when characteristic cutaneous lesions are present. Except for the pathognomonic appearance of reticular OLP (white striae occurring bilaterally on the buccal mucosa), in most cases histopathologic evaluation of lesional tissue is required to obtain a definitive diagnosis. Even classic cases of lichen planus

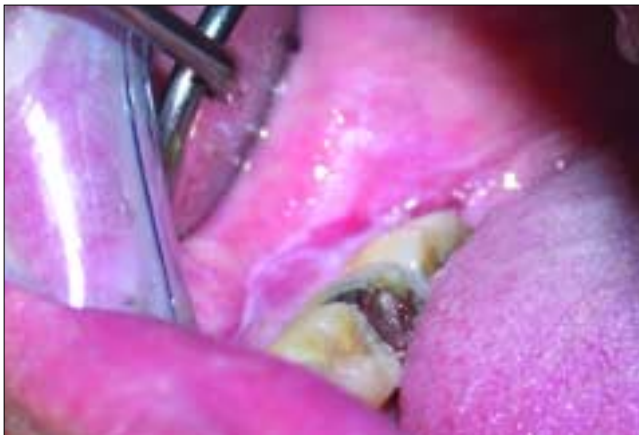

Figure 5: Erosive oral lichen planus involving the unattached gingiva.

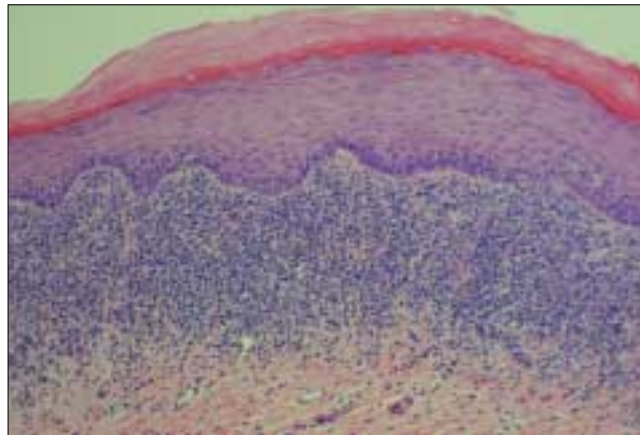


Figure 6: Histopathologic features of oral lichen planus, including dense band-like lymphocytic infiltrate at the interface between the epithelium and the connective tissue, hyperkeratinized epithelium and shortened rete pegs.

may be worthy of biopsy so as to establish baseline histopathologic features.

The differential diagnosis of erosive OLP includes squamous cell carcinoma, discoid lupus erythematosus, chronic candidiasis, benign mucous membrane pemphigoid, pemphigus vulgaris, chronic cheek chewing, lichenoid reaction to dental amalgam or drugs, graft-versus-host disease (GVHD), hypersensitivity mucositis and erythema multiforme.⁸ The plaque form of reticular OLP can resemble oral leukoplakia.

Biopsy Procedures

The definitive diagnosis of OLP depends on histopathologic examination of the affected tissue. However, performing a biopsy of lesional tissue, particularly if the OLP is of the erosive form, can be challenging. It is important to obtain an elliptical wedge of mucosa extending beyond the affected area, to avoid stripping the superficial epithelial layer from the underlying connective tissue.

Histopathologic Features

The classic histopathologic features of OLP include liquefaction of the basal cell layer accompanied by apoptosis of the keratinocytes, a dense band-like lymphocytic infiltrate at the interface between the epithelium and the connective tissue, focal areas of hyperkeratinized epithelium (which give rise to the clinically apparent Wickham's striae) and occasional areas of atrophic epithelium where the rete pegs may be shortened and pointed (a characteristic known as sawtooth rete pegs) (Fig. 6).⁸ Eosinophilic colloid bodies (Civatte bodies), which represent degenerating keratinocytes, are often visible in the lower half of the surface epithelium.

Although the histopathologic features of OLP are characteristic, other conditions, such as lichenoid reaction to dental amalgam and drugs, may exhibit a similar histologic pattern.

The histopathologic diagnosis of OLP can be complicated by the presence of superimposed candidiasis; diagnosis can

also be more difficult if the biopsy exhibits an ulcerated surface. In these situations, the biopsy findings are sometimes interpreted as representing a nonspecific chronic inflammatory process.⁹

On occasion, the histopathologic features are equivocal, and the oral pathologist examining the submitted tissue may recommend that a second biopsy be performed to obtain fresh tissue for immunofluorescence.¹⁰ Immunofluorescent examination of OLP lesional tissue usually demonstrates deposition of fibrinogen along the basement membrane zone. Chronic ulcerative stomatitis is a relatively recently described condition¹¹ that has light microscopic features similar to OLP but possesses a characteristic immunofluorescent pattern. It is reportedly less responsive to corticosteroid therapy than OLP.

If the biopsy report is equivocal, or does not agree with the clinical picture, it may be prudent to perform another biopsy, especially when dealing with isolated lesions occurring in locations where the risk of development of squamous cell carcinoma is higher, such as the lateral and ventral surfaces of the tongue and the floor of the mouth.

Clinical Significance of OLP

OLP is one of the most common mucosal conditions affecting the oral cavity.¹² Therefore, dentists in clinical practice will regularly encounter patients with this condition.

Because patients with the atrophic and erosive forms of OLP typically experience significant discomfort, knowledge of the treatment protocols available is important.

The similarity of OLP to several other vesiculo-ulcerative conditions, some of which can lead to significant morbidity, makes accurate diagnosis essential. For example OLP and GVHD can have similar histologic and clinical presentations. GVHD is a serious condition that occurs in bone marrow transplant patients when transplanted marrow cells react against host tissues. The extent of oral involvement is highly predictive of the severity and prognosis of GVHD.¹³

Table 1 Medications associated with mucosal lichenoid reactions¹⁴

Drug class
Antimalarials
Hydrochloroquine
Quinidine
Quinine
Nonsteroidal anti-inflammatory drugs
Indomethacin
Naproxen
Phenylbutazone
Diuretics
Furosemide
Hydrochlorothiazide
Antihypertensives
<i>Angiotensin-converting enzyme inhibitors</i>
Captopril
Enalapril
<i>Beta-blockers</i>
Propranolol
Antibiotics
Penicillin
Sulfonamides
Tetracycline
Antifungals
Ketoconazole
Heavy metals
Bismuth
Chromium
Mercury
Nickel
Miscellaneous
Allopurinol
Carbamazepine
Lithium
Lorazepam
Methyldopa
Oral contraceptives

Erosive OLP and lichenoid drug reactions can be indistinguishable both histologically and clinically. Some of the drugs commonly associated with lichenoid reactions are nonsteroidal anti-inflammatory drugs, diuretics, angiotensin-converting enzyme inhibitors, beta-blockers and antimicrobials (Table 1).¹⁴

It is also necessary to distinguish isolated erosive or reticular lesions from lichenoid reactions to dental amalgam.¹⁵ Lichenoid reactions to amalgam do not migrate, they occur on mucosal tissue in direct contact with the restoration, and they resolve once the amalgam restoration is removed.¹⁶

Some studies indicate an increased risk of squamous cell carcinoma in patients with OLP lesions.¹⁷⁻²⁰ This increased risk appears most common with the erosive and atrophic forms and in cases of lesions of the lateral border of the tongue. Other studies suggest that in some cases of purported malignant transformation, the malignancy may not have developed from true lesions of OLP but may instead have arisen from

areas of dysplastic leukoplakia with a secondary lichenoid inflammatory infiltrate.^{21,22} A review of previously published studies concluded that the risk of developing squamous cell carcinoma in patients with OLP is approximately 10 times higher than that in the unaffected general population.²³

Other published reports have noted a possible association between OLP and hepatitis C,²⁴ sclerosing cholangitis, and primary biliary cirrhosis.²⁵

Treatment

There is currently no cure for OLP. Excellent oral hygiene is believed to reduce the severity of the symptoms, but it can be difficult for patients to achieve high levels of hygiene during periods of active disease. Treatment is aimed primarily at reducing the length and severity of symptomatic outbreaks. Asymptomatic reticular and plaque forms of OLP do not require pharmacologic intervention.

Before initiating treatment, the diagnosis must be confirmed histologically. It is also important to rule out candidiasis, since many treatment modalities can aggravate an existing candidal infection.

Corticosteroids

The most widely accepted treatment for lesions of OLP involves topical or systemic corticosteroids to modulate the patient's immune response.

Topical corticosteroids are the mainstay in treating mild to moderately symptomatic lesions. Options (presented in terms of decreasing potency) include 0.05% clobetasol propionate gel,²⁶ 0.1% or 0.05% betamethasone valerate gel,⁶ 0.05% fluocinonide gel,²⁷ 0.05% clobetasol butyrate ointment or cream, and 0.1% triamcinolone acetonide ointment.²⁸

Patients are instructed to apply a thin layer of the prescribed topical corticosteroid up to 3 times a day, after meals and at bedtime. The gel or ointment can be applied directly or can be mixed with equal parts Orabase (a gelatin-pectin-sodium carboxymethylcellulose-based oral adhesive paste, ConvaTec, Division of Bristol-Myers Squibb, Montreal, Que.) to facilitate adherence to the gingival tissues. The choice of delivery vehicle depends on clinician and patient preference. In general, oral application is best accomplished with a gel preparation if available.

In patients with widespread symptomatic lesions, in whom direct mucosal application of topical medication would be too uncomfortable, options include 1.0 mg/mL aqueous triamcinolone acetonide or 0.1 mg/mL dexamethasone elixir. These solutions can be prepared by a compounding pharmacy. Patients should be instructed to gargle with 5 mL of the solution for 2 minutes after meals and at night. After rinsing, the solution should be expectorated, and nothing should be taken by mouth for one hour.

Alternative delivery methods include the use of cloth strips²⁹ and custom trays¹⁰ to serve as reservoirs for the corticosteroid.

The advantage of topical steroid application is that side effects are fewer than with systemic administration. Adverse

effects include candidiasis, thinning of the oral mucosa and discomfort on application. Topical formulations of the more potent corticosteroids can cause adrenal suppression if used in large amounts for prolonged periods or with occlusive dressings. The lowest-potency steroid that proves effective should be used.

Intralesional injection of corticosteroid²⁸ for recalcitrant or extensive lesions involves the subcutaneous injection of 0.2–0.4 mL of a 10 mg/mL solution of triamcinolone acetonide by means of a 1.0-mL 23- or 25-gauge tuberculin syringe.

Systemic steroid therapy should be reserved for patients in whom OLP lesions are recalcitrant to topical steroid management.

Because the dosage ranges for corticosteroids are wide and patient responses variable, numerous dosing options have been proposed.^{1,14,30,31} Dosages should be individualized according to the severity of the lesions and the patient's weight and should be modified on the basis of the patient's response to treatment. The oral dose of prednisone for a 70-kg adult ranges from 10–20 mg/day for moderately severe cases to as high as 35 mg/day (0.5 mg/kg daily) for severe cases.³¹ Prednisone should be taken as a single morning dose to reduce the potential for insomnia and should be taken with food to avoid nausea and peptic ulceration.

Significant response should be observed within one to 2 weeks.

When systemic corticosteroids are prescribed for periods of longer than 2 weeks, the dosage of steroid must be gradually tapered to avoid precipitating an adrenal crisis. Tapering can be accomplished by decreasing the daily dose of prednisone by 5 mg per week.

The potential side effects of short-term systemic steroid therapy are numerous. They include insomnia, diarrhea, disturbances of the central nervous system including psychotic episodes, sodium and fluid retention, muscle weakness, decreased resistance to infection, hypertension, hyperglycemia and adrenal suppression.³²

Steroid use is contraindicated in patients who are breastfeeding. Steroids should be used with caution in patients with herpetic infections, glaucoma, pregnancy, HIV infection, tuberculosis, diabetes mellitus and hypertension.

The prophylactic use of a 0.12% chlorhexidine gluconate rinse may help reduce the incidence of fungal infection during corticosteroid therapy.³³ An alcohol-free rinse (available at most compounding pharmacies) should be prescribed to avoid desiccation and irritation of the oral tissues. If secondary growth of candidal organisms is confirmed, antifungal agents should be prescribed.

Other Approaches

Twice-daily topical application of compounded 0.1% tacrolimus ointment was recently reported to be effective in controlling symptoms as well as clearing lesions of OLP.^{34,35} Tacrolimus is a macrolide immunosuppressant with a mechanism of action similar to that of cyclosporine, but is 10 to

100 times more potent and is better able to penetrate the mucosal surface.³⁵

Other documented treatment modalities include retinoids and vitamin A analogues, cyclosporine rinse, the immunomodulating agent levamisole, PUVA treatment (which consists of administration of 8-methoxypsoralen and exposure to long-wave ultraviolet A light), dapsone, griseofulvin, azathioprine and cryotherapy.³¹

A recent systematic review by the Cochrane group³⁶ of all published reports of randomized placebo-controlled trials of palliative treatment for patients with symptomatic OLP concluded that there was only weak evidence that the evaluated treatments were superior to placebo. Specifically, 9 qualifying studies examining the effect of topical steroids, topical cyclosporine, and topical and systemic retinoids were analyzed. The authors of the review concluded that although most of the studies showed demonstrable treatment effects, the results should be interpreted with caution because of small sample sizes, lack of independent corroboration and difficulty in accurately measuring the results of treatment.

Even though evidence of the efficacy of these treatment approaches is not overwhelming, corticosteroid therapy remains the most common approach for managing symptomatic lesions.

Because of the possibility of increased risk of malignant transformation, periodic reassessment of all patients with OLP is recommended.

Conclusion

Patients with OLP should be counselled as to the nature of this chronic condition and the different approaches to treatment. Patients should be informed that they may experience alternating periods of symptomatic remission and exacerbation. Clinicians should maintain a high index of suspicion for all intraoral areas that appear unusual, even in patients with a histologically confirmed diagnosis of OLP. This vigilance is especially important for isolated lesions occurring in locations at higher risk for the development of squamous cell carcinoma, such as the lateral and ventral surfaces of the tongue and the floor of the mouth. ♦

Remerciements : Les auteurs aimeraient remercier le Dr John Fantasia, directeur de la Division de pathologie buccale et maxillo-faciale, Département de médecine dentaire, Centre médical juif de Long Island, New Hyde Park (New York), pour son assistance dans la révision de ce manuscrit.

Le Dr Edwards est résident, Département de médecine dentaire, Division de pathologie buccale, Centre médical juif de Long Island, New Hyde Park (New York).

Le Dr Kelsch est assistant traitant, Division de pathologie buccale, Centre médical juif de Long Island, New Hyde Park (New York).

Écrire au : Dr Paul C. Edwards, Department of Dental Medicine, Long Island Jewish Medical Center, 270-05 76th Avenue, New Hyde Park, New York, 11040, USA. Courriel : dental919@hotmail.com.

Les auteurs n'ont aucun intérêt financier déclaré dans la ou les sociétés qui fabriquent les produits mentionnés dans cet article.

Références

1. McCreary CE, McCartan BE. Clinical management of lichen planus. *Brit J Oral Maxillofacial Surg* 1999; 37(5):338-43.
2. Mollaoglu N. Oral lichen planus: a review. *Brit J Oral Maxillofacial Surg* 2000; 38(4):370-7.
3. Sapp JP, Eversole LR, Wysocki GP. Contemporary oral and maxillofacial pathology. St. Louis (MI): Mosby; 1997.
4. Rodriguez-Nunez I, Blanco-Carrion A, Garcia AG, Rey JG. Peripheral T-cell subsets in patients with reticular and atrophic-erosive oral lichen planus. *Oral Surg Oral Med Oral Pathol Oral Radiol Endod* 2001; 91(2):180-8.
5. Brown RS, Bottomley WK, Puente E, Lavigne GL. A retrospective evaluation of 193 patients with oral lichen planus. *J Oral Pathol Med* 1993; 22(5):69-72.
6. Jungell P. Oral lichen planus: a review. *Int J Oral Maxillofac Surg* 1991; 20(3):129-35.
7. Katta R. Lichen planus. *Am Fam Physician* 2000; 61(11):3319-28.
8. Regezzi JA, Sciubba JJ. Oral pathology: clinical pathologic correlations. 3rd ed. Philadelphia: WB Saunders; 1999.
9. Burgess KL, McComb RJ. The gingivae in dermatoses. *Ont Dent* 1997; 74(5):25-9.
10. Murrah VA, Perez LM. Oral lichen planus: parameters affecting accurate diagnosis and effective management. *Pract Periodontics Aesthet Dent* 1997; 9(6):613-20.
11. Lewis JE, Beutner EH, Rostami R, Chorzelski TP. Chronic ulcerative stomatitis with stratified epithelium-specific antinuclear antibodies. *Int J Dermatol* 1996; 35(4):272-5.
12. Pynn BR, Burgess KL, Wade PS, McComb RJ. A retrospective survey of 2021 patients referred to the Toronto Hospital Mouth Clinic. *Ont Dent* 1995; 72(1):21-4.
13. Neville BW, Damm DD, Allen CM, Bouquot JE. Oral and maxillofacial pathology. 2nd ed. Philadelphia: WB Saunders; 2002.
14. Bernstein ML. The diagnosis and management of chronic nonspecific mucosal lesions. *J Calif Dent Assoc* 1999; 27(4):290-9.
15. Ostman PO, Anneroth G, Skoglund A. Oral lichen planus lesions in contact with amalgam fillings: a clinical, histologic, and immunohistochemical study. *Scand J Dent Res* 1994; 102(3):172-9.
16. Damm DD, Fantasia JE. Radiating white lesion of the ventral surface of the tongue. *Gen Dent* 1993; 41(1):26.
17. Silverman S Jr, Bahl S. Oral lichen planus update: clinical characteristics, treatment responses, and malignant transformation. *Am J Dent* 1997; 10(6):259-63.
18. Barnard NA, Scully C, Eveson JW, Cunningham S, Porter SR. Oral cancer development in patients with oral lichen planus. *J Oral Pathol Med* 1993; 22 (9):421-4.
19. Holmstrup P. The controversy of a premalignant potential of oral lichen planus is over. *Oral Surg Oral Med Oral Pathol* 1992; 73(6):704-6.
20. Silverman S. Oral lichen planus: a potentially premalignant lesion. *J Oral Maxillofacial Surg* 2000; 58(11):1286-8.
21. Eisenberg E, Krutchkoff DJ. Lichenoid lesions of oral mucosa. Diagnostic criteria and their importance in the alleged relationship to oral cancer. *Oral Surg Oral Med Oral Pathol* 1992; 73(6):699-703.
22. Eisenberg E. Oral lichen planus: a benign lesion. *J Oral Maxillofacial Surg* 2000; 58(11):1278-85.
23. Drangsholt M, Truelove EL, Morton TH Jr, Epstein JB. A man with a thirty-year history of oral lesions. *J Evid Base Dent Pract* 2001; 1(2): 123-35.
24. Bellman B, Reddy RK, Falanga V. Lichen planus associated with hepatitis C. *Lancet* 1995; 346(8984):1234.
25. Fantasia JE. Diagnosis and treatment of common oral lesions found in the elderly. *Dent Clin North Am* 1997; 41(4):877-90.
26. Muzio LL, della Valle A, Mignogna MD, Pannone G, Bucci P, Bucci E, and other. The treatment of oral aphthous ulceration or erosive lichen planus with topical clobetasol propionate in three preparations: a clinical and pilot study on 54 patients. *J Oral Pathol Med* 2001; 30(10):611-7.
27. Voute AB, Schulten EA, Langendijk PN, Kostense PJ, van der Waal I. Fluocinonide in an adhesive base for treatment of oral lichen planus: a double-blind, placebo-controlled clinical study. *Oral Surg Oral Med Oral Pathol* 1993; 75(2):181-5.
28. Vincent SD. Diagnosing and managing oral lichen planus. *JADA* 1991; 122(6):93-6.
29. Aleinikov A, Jordan RC, Main JH. Topical steroid therapy in oral lichen planus: review of a novel delivery method in 24 patients. *J Can Dent Assoc* 1996; 62(4):324-7.
30. Sinz DE, Kaugars GE. Corticosteroid therapy in general dental practice. *Gen Dent* 1992; 40(4):298-9.
31. Carrozzo M, Gandolfo S. The management of oral lichen planus. *Oral Dis* 1999; 5(3):196-205.
32. Mackay S, Eisendrath S. Adverse reaction to dental corticosteroids. *Gen Dent* 1992; 40(2):136-8.
33. Ellepola AN, Samaranyake LP. Adjunctive use of chlorhexidine in oral candidoses: a review. *Oral Dis* 2001; 7(1):11-7.
34. Rozycki TW, Rogers RS 3rd, Pittelkow MR, McEvoy MT, el-Azhary RA, Bruce AJ, and others. Topical tacrolimus in the treatment of symptomatic oral lichen planus: a series of 13 cases. *J Am Acad Dermatol* 2002; 46(1):27-34.
35. Kaliakatsou F, Hodgson TA, Lewsey JD, Hegarty AM, Murphy AG, Porter SR. Management of recalcitrant ulcerative oral lichen planus with topical tacrolimus. *J Am Acad Dermatol* 2002; 46(1):35-41.
36. Chan ES, Thornhill M, Zakrzewska J. Interventions for treating oral lichen planus. *Cochrane Database Syst Rev* 2000; 18(2):CD 001168.