

Capecitabine-induced lichenoid drug eruption: a case report

Jeff R. Gehlhausen PhD¹, Matthew B. Strausburg MD², Mouhammad Aouthmany MD², Terrence M. Katona³, Matthew J. Turner MD, PhD³

Affiliations: ¹Department of Biochemistry and Molecular Biology, Indiana University School of Medicine, Indianapolis, Indiana, ²Department of Dermatology, Indiana University School of Medicine, Indianapolis, Indiana, ³Richard L. Roudebush VA Medical Center, Indianapolis, Indiana

Corresponding Author: Matthew J. Turner, Address: 545 Barnhill Dr (EH139); Indianapolis, IN 46202, Telephone: 317-274-7740, Fax: 317-274-3700, Email: turner41@iu.edu

Abstract

Capecitabine is a 5-fluorouracil based chemotherapeutic drug widely used in the treatment of solid tumors, especially colorectal and breast. Some of the most common side effects of capecitabine are cutaneous in nature, including hand-foot syndrome (palmar-plantar erythrodysesthesia). Several reports in the literature link capecitabine use with photosensitive lichenoid eruptions. Herein, we present a case of capecitabine-induced lichenoid eruption in an elderly female with metastatic breast cancer and discuss our findings in relationship to previously reported cases of this and other capecitabine-induced skin pathologies.

Keywords: capecitabine, lichenoid, drug eruption, photosensitive, 5-fluorouracil

Introduction

Capecitabine, an oral prodrug of the chemotherapeutic 5-fluorouracil (5-FU), is used in the treatment of advanced colorectal, esophageal, laryngeal, and breast cancers. 5-FU exerts its effects by blocking

DNA synthesis through inhibition of the enzyme thymidylate synthetase, thereby sensitizing rapidly growing cells to cell death. Systemic use of 5-FU was long ago shown to result in skin photosensitivity, as well as an inflammatory reaction in actinic keratoses [1,2]. On this basis, it has been suggested that the anti-tumor activity observed by topical 5-FU on actinic keratoses is in part related to the production of an immunologic reaction in tandem with its anti-metabolite function [3]. Prodrugs of 5-FU (e.g. capecitabine) have also been reported to cause a variety of cutaneous eruptions [4-7] (**Table 1**). Herein, we describe a patient with a photosensitive lichenoid eruption developing during treatment with capecitabine and discuss our findings in the context of similar cases in the literature.

Case Synopsis

A 61-year-old woman with metastatic breast cancer presented to dermatology clinic for a three-week history of a progressive nonpruritic eruption on the arms. She reported the eruption started with pinpoint-sized erythematous macules that later evolved into scaly erythematous patches. One week

Table 1. *Mucocutaneous side effects of Capecitabine. Table adapted with permission from Walker et al [6].*

Hand-Foot syndrome	Palmoplantar burning and erythema. Most common cutaneous reaction (7).
Nail toxicity	Onycholysis and onychomadesis (4).
Stomatitis	Tongue and buccal mucosa (6).
Subacute cutaneous lupus erythematosus	Photodistributed erythematous papules and plaques (6).
Miscellaneous	Dermatitis, xerosis, alopecia, bullous eruptions (5).

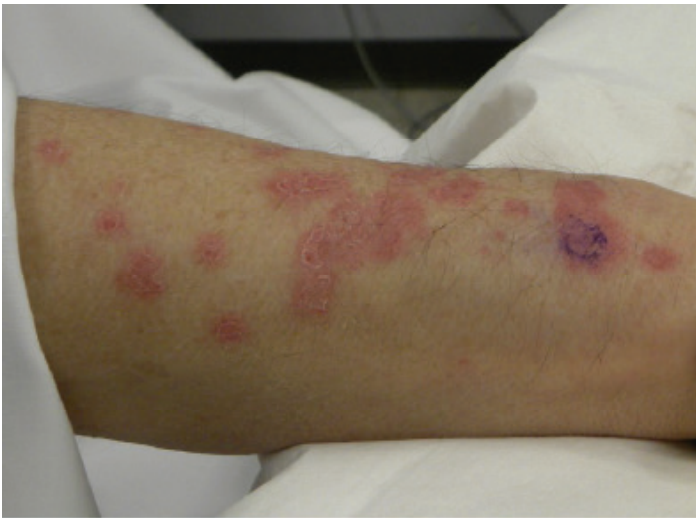

Figure 1: Capecitabine-induced lichenoid drug eruption on dorsal forearm.

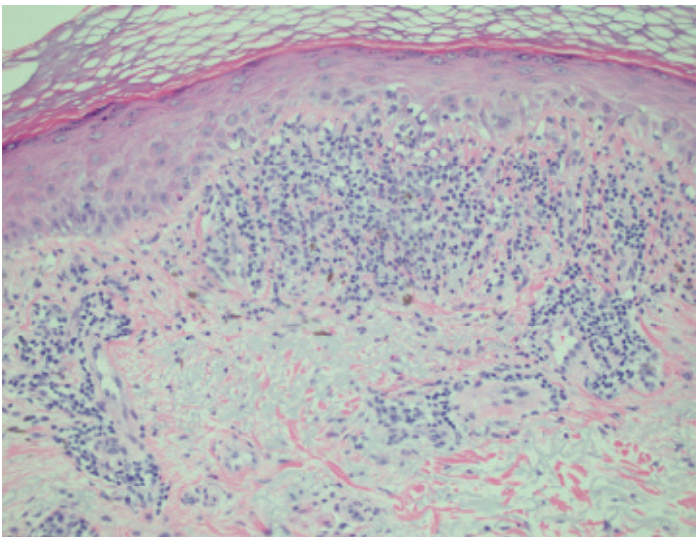


Figure 2: Haematoxylin and Eosin stain of biopsy displaying lymphocytic infiltrate and basal layer vacuolization. Original magnification 100x.

prior to the onset of this eruption, she had completed three consecutive 21-day cycles of capecitabine for breast cancer. Physical examination of the dorsum of the hands and forearms was remarkable for scattered variably sized erythematous patches and thin plaques with a small amount of peripheral scale (**Figure 1**). Serological testing for ANA was negative. A biopsy revealed basal layer vacuolization, a superficial and deep lymphocyte-rich inflammatory infiltrate that focally obscured the dermoepidermal junction, pigment incontinence, and scattered necrotic cells in the dermis (**Figure 2**). Based on these clinicopathologic findings, a diagnosis of capecitabine-induced (photosensitive) lichenoid eruption was made.

The patient was counseled regarding sun avoidance and protection and instructed to apply triamcinolone 0.1% ointment twice daily to the affected areas. She remained off of capecitabine, initiated photoprotective measures, and started treatment with topical triamcinolone; at her one-month follow-up appointment, the patches and plaques were significantly smaller and less erythematous. After this visit, the patient resumed capecitabine and experienced a flare of her eruption along with a burning sensation in the involved areas. Physical exam during the flare revealed confluent pink to violaceous plaques on the dorsum of the hands and forearms. She denied any benefit of using triamcinolone ointment for the flare.

Discussion

Several types of drug eruptions are associated with 5-FU-based prodrugs like capecitabine. Hand-Foot syndrome (HFS), also known as palmar-plantar erythrodysesthesia, is the most common capecitabine-related adverse event and is observed in 45-68% of patients [8]. This eruption is characterized by palmoplantar erythema in conjunction with numbness, dysesthesia, and/or paresthesia. Other mucocutaneous eruptions associated with capecitabine (**Table 1**) include nail and periungual reactions, oral lichenoid stomatitis, subacute cutaneous lupus erythematosus (SCLE), and capecitabine-induced lichenoid drug eruption [6,7,9].

It is interesting to note that despite the decades of use and many documented cases of cutaneous reactions after administration of 5-FU, there are, to our knowledge, no reported cases of lichenoid eruptions [10]. Lichenoid eruptions have been observed with the use of another 5-FU prodrug, Tegafur (1-(2-tetrahydrofuryl)-5-fluorouracil) [11]. This would suggest that perhaps the lichenoid reaction seen with 5-FU prodrugs might in fact be related to a metabolite of the prodrugs rather than 5-FU.

To our knowledge, only three other cases of capecitabine-induced lichenoid drug eruption have been described in the literature [6,7,9]. Interestingly, all four reported cases of capecitabine-induced lichenoid drug eruption occurred in elderly women; the significance of this observation is unclear but

notable. Our patient experienced some improvement upon drug discontinuation in conjunction with observation of photoprotective measures and application of topical corticosteroids. However, these latter interventions offered no significant benefit when the patient resumed therapy with capecitabine. Regarding previously reported cases, one patient experienced resolution of her eruption six weeks after discontinuation of capecitabine, whereas the other two demonstrated improvement with administration of topical steroids despite continuation of capecitabine [5,6,12]. Specifically,

one of the patients observed an overall decrease in the number of lesions after topical halobetasol treatment [12], whereas the other patient noted improvement in her eruption with topical clobetasol and photoprotective measures; the nature of this improvement was not mentioned [6]. Our patient and those reported elsewhere in the literature suggest moderate potency topical corticosteroids and photoprotection have some therapeutic efficacy in patients with capecitabine-induced lichenoid drug eruption. These cases are reviewed in **Table 2**.

Table 2. Findings in previous cases of capecitabine-induced lichenoid eruption.

Age/sex	Temporal association with capecitabine	Morphology	Distribution	Histology	Labs	Treatment
73/F	1 week after initiation	Erythematous plaques	Neck and arms	Focal hyperkeratosis including parakeratosis. Epidermal atrophy. Basal layer vacuolization. Perivascular lymphocytic infiltrate and pigment incontinence. DIF negative for Immunoglobulin and complement.	None reported	Eruption resolved after discontinuing capecitabine (5).
56/F	2 weeks after initiation	Erythematous papules and plaques	Photodistribution on trunk and extremities	Occasional necrotic keratinocytes. Basal layer vacuolization. Superficial and mid-dermal perivascular infiltrate of uniform lymphocytes.	None reported	Treatment with halobetasol, loratidine, and photoprotection, despite continuing capecitabine, reduced the extent of disease though new lesions continued to develop (12).
75/F	2 months after initiation	Violaceous papules and scaling erythema	Photodistribution on forearms, dorsal hands, and anterior aspect of legs. Also associated nail changes.	Compact orthokeratosis. Lichenoid interface dermatitis. Scattered melanophages and few eosinophils in dermis.	None reported	Improvement noted with clobetasol 0.05% ointment, hydroxyzine, and photoprotection despite continuing capecitabine therapy (6).
61/F	1 week after completing a cycle of therapy	Erythematous patches with scale	Extensor forearms and dorsal hands	Basal layer vacuolization. Superficial and deep lymphocyte-rich inflammatory infiltrate. Pigment incontinence and scattered necrotic cells in the dermis.	ANA negative	Minimal improvement with triamcinolone 0.1% ointment and photoprotection. The eruption improved with discontinuation of capecitabine and flared when treatment with capecitabine resumed (present case).

The differential diagnosis for capecitabine-induced lichenoid drug eruption includes capecitabine-induced inflammation of actinic keratoses, which can present with pruritic, erythematous scaling macules and papules on sun-exposed areas of the skin [13]. In our case, both diagnoses were considered but examination of the biopsy findings conclusively ruled out the diagnosis of inflammation of actinic keratoses. Other diagnoses to consider include SCLE and erythema multiforme. Histologically, these entities do not typically display the broad lichenoid infiltrate that was seen in our patient's biopsy specimen, but rather predominantly display vacuolar changes. The negative ANA further argues against SCLE, as previous studies have found that over 80% of drug-induced SCLE patients have positive ANA lab values [14]. Other histologic features present in this case that favor a lichenoid drug reaction include individual apoptotic keratinocytes located above the basal layer of the epidermis, the presence of plasma cells in the infiltrate, and pigment incontinence in the dermis.

Conclusion

In closing, we describe a rarely reported cutaneous adverse event of capecitabine and highlight other mucocutaneous adverse events associated with this and related medications.

References

1. Omura EF, Torre D. Inflammation of actinic keratoses due to systemic fluorouracil therapy. *Jama*. 1969;208(1):150-1. [PMID: 5818500]
2. Falkson G, Schulz EJ. Skin changes in patients treated with 5-fluorouracil. *The British journal of dermatology*. 1962;74:229-36. [PMID: 13891467]
3. Mansell PW, Litwin MS, Ichinose H, Kremenz ET. Delayed hypersensitivity to 5-fluorouracil following topical chemotherapy of cutaneous cancers. *Cancer research*. 1975;35(5):1288-94. [PMID: 1120313]
4. Chen GY, Chen YH, Hsu MM, Tsao CJ, Chen WC. Onychomadesis and onycholysis associated with capecitabine. *The British journal of dermatology*. 2001;145(3):521-2. [PMID: 11531857]
5. Hague JS, Ilchysyn A. Lichenoid photosensitive eruption due to capecitabine chemotherapy for metastatic breast cancer. *Clinical and experimental dermatology*. 2007;32(1):102-3. doi: 10.1111/j.1365-2230.2006.02245.x. [PMID: 16879449]
6. Walker G, Lane N, Parekh P. Photosensitive lichenoid drug eruption to capecitabine. *Journal of the American Academy of Dermatology*. 2014;71(2):e52-3. doi: 10.1016/j.jaad.2014.01.884. [PMID: 25037814]
7. Weger W, Kranke B, Gerger A, Salmhofer W, Aberer E. Occurrence of subacute cutaneous lupus erythematosus after treatment with fluorouracil and capecitabine. *Journal of the American Academy of Dermatology*. 2008;59(2 Suppl 1):S4-6. doi: 10.1016/j.jaad.2007.06.040. [PMID: 18625380]
8. Heo YS, Chang HM, Kim TW, Ryu MH, Ahn JH, Kim SB, Lee JS, Kim

- WK, Cho HK, Kang YK. Hand-foot syndrome in patients treated with capecitabine-containing combination chemotherapy. *Journal of clinical pharmacology*. 2004;44(10):1166-72. doi: 10.1177/0091270004268321. [PMID: 15342618]
9. Mignogna MD, Fortuna G, Falletti J, Leuci S. Capecitabine-induced stomatitis: a likely pathogenetic mechanism of oral lichenoid mucositis. *European journal of clinical pharmacology*. 2009;65(10):1057-9. doi: 10.1007/s00228-009-0674-z. [PMID: 19521695]
10. Vukelja SJ, Bonner MW, McCollough M, Cobb PW, Gaule DA, Fanucchi PJ, Keeling JH. Unusual serpentine hyperpigmentation associated with 5-fluorouracil. Case report and review of cutaneous manifestations associated with systemic 5-fluorouracil. *Journal of the American Academy of Dermatology*. 1991;25(5 Pt 2):905-8. [PMID: 1837033]
11. Horio T, Yokoyama M. Tegaful photosensitivity-lichenoid and eczematous types. *Photo-dermatology*. 1986;3(3):192-3. [PMID: 3092199]
12. Willey A, Glusac EJ, Bologna JL. Photoeruption in a patient treated with capecitabine (Xeloda) for metastatic breast cancer. *Journal of the American Academy of Dermatology*. 2002;47(3):453. [PMID: 12196762]
13. Krathen M, Treat J, James WD. Capecitabine induced inflammation of actinic keratoses. *Dermatology online journal*. 2007;13(4):13. Epub 2008/03/06. [PMID: 18319010]
14. Lowe GC, Henderson CL, Grau RH, Hansen CB, Sontheimer RD. A systematic review of drug-induced subacute cutaneous lupus erythematosus. *The British journal of dermatology*. 2011;164(3):465-72. doi: 10.1111/j.1365-2133.2010.10110.x. [PMID: 21039412]