

**C-KIT EXPRESSION IN THE SALIVARY GLAND NEOPLASMS ADENOID
CYSTIC CARCINOMA, POLYMORPHOUS LOW GRADE
ADENOCARCINOMA AND MONOMORPHIC ADENOMA**

Paul C. Edwards¹ M.Sc., D.D.S., T. Bhuiya² M.D., and R. Kelsch³ D.M.D.

¹Department of Dental Medicine, Division of Oral Pathology, Long Island Jewish Medical Center, New Hyde Park, NY,

²Head, Division of Surgical Pathology, Department of Pathology, Long Island Jewish Medical Center, New Hyde Park, NY, and

³Head, Section of Clinical Oral Pathology, Division of Oral Pathology, Department of Dental Medicine, Long Island Jewish Medical Center, New Hyde Park, NY.

Author's accepted manuscript; final version published as:

Edwards PC, Bhuiya T, Kelsch RD. C-kit expression in the salivary gland neoplasms adenoid cystic carcinoma, polymorphous low-grade adenocarcinoma, and monomorphic adenoma. Oral Surg Oral Med Oral Pathol Oral Radiol Endod. 2003 May;95(5):586-93.

**C-KIT EXPRESSION IN THE SALIVARY GLAND NEOPLASMS ADENOID
CYSTIC CARCINOMA, POLYMORPHOUS LOW GRADE
ADENOCARCINOMA AND MONOMORPHIC ADENOMA**

Author's accepted manuscript; final version published as:

Edwards PC, Bhuiya T, Kelsch RD. C-kit expression in the salivary gland neoplasms adenoid cystic carcinoma, polymorphous low-grade adenocarcinoma, and monomorphic adenoma. Oral Surg Oral Med Oral Pathol Oral Radiol Endod. 2003 May;95(5):586-93.

This manuscript was presented at the:

American Academy of Oral and Maxillofacial Pathology Annual Meeting,
New Orleans, LA,
April 22, 2002.

ABSTRACT

The tyrosine kinase receptor protein c-kit exerts a broad range of activities during organogenesis and normal cell development. It is involved in the development of multiple haematopoietic cell lines, mast cells, melanogenesis, interstitial cells of Cajal and gametogenesis. Recent studies have revealed that over-expression of c-kit protein occurs in a narrow subset of malignant neoplasms, including gastrointestinal stromal tumors, myeloid leukemias, seminomas and adenoid cystic carcinomas (ACC). C-kit reportedly is not expressed in polymorphous low-grade adenocarcinoma (PLGA).

We examined the expression of the c-kit antigen in the malignant salivary gland neoplasms ACC and PLGA and compared it to its expression in the benign salivary gland tumor monomorphic adenoma (including trabecular adenoma, canalicular adenoma and basal cell adenoma).

Formalin-fixed paraffin-embedded sections of 49 salivary gland neoplasms (17 monomorphic adenomas, 17 PLGA and 15 ACC) accessioned between 1989 and 2002 were retrieved from the files of the Department of Pathology, Long Island Jewish Medical Center, New Hyde Park, NY, and were stained with an anti-c-kit polyclonal antibody.

C-kit reactivity was uniformly positive in the cytoplasm of luminal neoplastic cells in ACCs (15/15, 100%). Positive reactivity was also identified in the majority of PLGAs (16/17, 94%), with at least 25% of the tumor cells being positive. Similar reactivity was seen in monomorphic adenomas (16/17, 94%). In the normal surrounding salivary gland tissue, c-kit reactivity was identified only focally in ductal epithelium.

In contrast to previous reports, we find that c-kit expression was not restricted to ACC but was expressed in all three tumor types evaluated (ACC, PLGA and monomorphic adenoma). Therefore, c-kit does not appear to be an ideal marker for distinguishing between ACC and PLGA in equivocal cases, or benign from malignant salivary gland neoplasms.

INTRODUCTION

The transmembrane tyrosine kinase receptor c-kit (CD117) is a 145 to 165 kD proto-oncogene that is structurally related to the platelet-derived growth factor (PDGF) receptor and the colony stimulatory factor (CSF) receptor¹. Binding of its ligand (alternatively known as steel factor, stem cell factor, and mast cell growth factor) promotes phosphorylation, which subsequently activates a signaling cascade that regulates cell growth and development.

C-kit is expressed in a range of normal developmental pathways, including hematopoiesis and spermatogenesis. It is required for the normal migration and development of germ cells and melanocytes¹. It has been shown that mice bearing mutations in this gene locus are characterized by severe macrocytic anemia, lack of pigmentation and sterility.

In normal human tissue, c-kit is expressed in melanocytes, breast epithelium cells, mast cells², and the interstitial cells of Cajal³, which initiate and propagate slow muscle activity in gastrointestinal muscles.

Over-expression of this tyrosine kinase receptor has been reported in a subset of malignant neoplasms such as gastrointestinal stromal tumors (GIST)⁴, myeloid leukemia, testicular germ cell tumors⁵, endometrial carcinomas, papillary and follicular thyroid carcinomas⁵, renal and hepatic angiomyolipoma⁶, synovial sarcoma⁷, osteosarcoma⁷ and Ewing's sarcoma⁷.

In human salivary gland neoplasms, reports of c-kit expression have been contradictory. Several reports have suggested that c-kit is expressed in ACC. It is reportedly absent in PLGA^{1,8,9}. Based on these findings, it has been suggested that c-kit expression may be a suitable immunohistochemical marker to aid in distinguishing between these two neoplasms.

The purpose of this study was to compare the extent of c-kit immunoreactivity in adenoid cystic carcinoma, polymorphous low-grade adenocarcinoma and monomorphic adenoma.

MATERIALS AND METHODS

Formalin-fixed paraffin-embedded sections of 49 salivary gland neoplasms (17 monomorphic adenomas, 17 PLGA and 15 ACC) accessioned between 1989 and 2002 were retrieved from the files of the Department of Pathology, Long Island Jewish Medical Center.

The H&E stained slides were independently reviewed by three experienced pathologists (RK, JF, TB) and agreement was reached on all cases included in this study using accepted criteria¹⁰.

Microwave heat-induced epitope retrieval (750 W microwave at medium power, 30 minutes) was performed using the Trilogy™ system (Cell Marque, Hot Springs AK) as per the manufacturer's directions and then treated with anti-human c-kit polyclonal antibody (Dako, Kyoto, Japan) at a 1:100 dilution.

The antibody-antigen complex was detected using an indirect biotin-avidin system as per the manufacturer's instructions (Ventana Basic DAB Detection Kit™, Ventana Medical Systems, Tucson AZ).

Large cell undifferentiated lung carcinoma was used as positive controls for the c-kit marker. Normal salivary gland tissue was used as the negative control.

Immunoreactivity was independently assessed by all study participants. Agreement was reached on all 49 specimens examined. Immunoreactivity was considered positive if greater than 10% of the tumor cells stained and was graded as weak (10-25%), mild (26-50%), moderate (51-75%) and strong (76-100%).

RESULTS

The ACC group, comprising 12 women and 3 men, had a median age of 65 years (range: 37-89 years). The tumor group included 8 lesions of minor salivary gland origin (4 palate, 3 soft tissue of the neck, 1 maxillary sinus) and 7 lesions of major gland origin (5 parotid, 2 submandibular gland).

The median age of the PLGA group was 67 years (range: 38-73 years) and consisted of 13 female patients and 4 male patients. All tumors arose from minor salivary gland tissue, primarily palate (8) and buccal mucosa (4), except for one of parotid origin.

The monomorphic adenoma group, comprising 14 women and 3 men, had a median age of 66 years (range: 41-97). The tumors were located in the upper lip (9), parotid (4), buccal mucosa (3), and hard palate (1).

C-kit expression (Table 1) was evident in 15/15 ACCs as indicated by positive immunoreactivity. Cytoplasmic staining was identified in the luminal neoplastic cells in ACC (Fig.1). C-kit expression was more prominent in solid variants of ACC. The intensity of staining was strongest in ACCs of minor salivary gland origin (Table 2).

Positive reactivity was also noted in the majority of PLGAs (16/17, 94%) with at least 25% of the tumor cells being positive (Table 1, Fig.2). However, there was variable immunoreactivity, ranging from faint focal to strong positivity. The overall intensity of staining was weaker in PLGA as compared to ACC.

Similar positive immunoreactivity (16/17, 94%) was identified in monomorphic adenomas (Table 1, Fig.3). Expression was primarily noted in the luminal cells as in ACC, but the overall intensity was weaker than in ACC.

In the normal surrounding salivary gland tissue, c-kit reactivity was focally detected in the ductal epithelium.

DISCUSSION

Overlapping features of infiltrating tubular and solid growth patterns combined with a tendency for perineural invasion can make the light microscopic distinction between PLGA and ACC challenging. In addition, canalicular and basal cell adenomas (monomorphic adenomas) can bear a striking resemblance to ACC, especially when examining tissue obtained from small or fragmented incisional biopsies.

This study attempts to identify a highly specific immunohistochemical marker to distinguish between these entities, which to date has proven elusive.

C-Kit Expression in ACC, PLGA and Monomorphic Adenoma

In this study, the results showed that c-kit expression was not restricted to ACC but was significantly expressed in all three tumor types evaluated.

Our finding that c-kit expression is positive in all ACCs examined is in agreement with previously published results^{11, 12}, which reported that c-kit expression is highly positive in ACC, particularly solid variants^{13, 14}.

The intensity of staining is also of interest. In our study, strong staining (>75% of neoplastic cells) was identified in 43 % of ACCs of major salivary gland origin compared with 100 % of ACCs of minor salivary gland origin. In contrast, Oprea et al¹⁵ reported that expression was lower in ACC arising in minor salivary glands as opposed to major salivary gland ACCs, whereas Holst¹⁴ found no difference. Since c-kit reactivity is strongest in solid variants of ACC, variations in the predominant subtypes of ACC in different studies could account for these differences. In our study, there was a predominance of solid variant ACC in the minor salivary gland subgroup.

Published reports of c-kit immunohistochemical reactivity in ACC have been contradictory.

In an abstract comparing staining between ACC and PLGA, Penner et al⁸ reported cytoplasmic c-kit expression in 6 of 6 ACCs from major and minor salivary glands, but only 1 of 3 polymorphous low-grade adenocarcinomas (PLGAs). In a subsequent manuscript⁹, they identified weak c-kit immunoreactivity in 8/14 (57%) PLGAs. The intensity of c-kit staining was reportedly much stronger in ACC as compared to PLGA. Jeng et al¹ found moderate to strong c-kit expression in ACC (3/4 tubular ACC, 8/17 cribriform ACC and 4/4 solid ACC), but no expression in PLGA (0/4).

In contrast, our results concur with the findings of Cohn et al¹⁶. They reported that ACC (8/8) and PLGA (7/8) demonstrated similar immunostaining patterns, with strong immunoreactivity in both neoplasms.

The contradictory and disparate c-kit immunostaining results seen in PLGA are similar to the often divergent results reported between different studies of c-kit expression in soft tissue tumors¹⁷. These differences are likely due in part to the limited number of cases examined in individual reports and to variations in the experimental protocols and

antibodies employed. Hornick and Fletcher¹⁷ concluded that variations in immunohistochemical technique could lead to major discrepancies in positive staining.

Jeng et al¹ employed a pressure cooker for epitope retrieval and used a different polyclonal anti-c-kit antibody (Medical and Biological Laboratories, Nagoya, Japan) than was used in this study (Dako, Kyoto, Japan). The Dako anti-c-kit antibody, used at a dilution of 1:100 in this study, reportedly has low background staining and is the antibody specified in the multi-center trial of Gleevec chemotherapy in GIST¹⁷. Penner et al⁹ also used the Dako antibody, but at a lower concentration (1:200) and with a pressure cooker for epitope retrieval.

No published studies to date have compared expression of c-kit in ACC or PLGA to the benign salivary gland neoplasm monomorphic adenoma. In our present study, we found no evidence of differences in c-kit staining between these neoplasms.

Selective Immunohistochemical Markers in ACC, PLGA and Monomorphic Adenoma

Other immunohistochemical markers have been reported to be of possible benefit in distinguishing between ACC, PLGA and monomorphic adenoma.

It has been reported¹⁸ that S-100 immunoreactivity may be of value in differentiating ACC from PLGA. Although S-100 is positive in both neoplasms, staining is reportedly more diffuse and stronger in PLGA as compared to ACC. Strong S-100 and weak actin staining of PLGA compared to weak S-100 and moderate actin staining of ACC may aid in separating these two entities¹⁸.

Araujo et al¹⁹, comparing cribriform areas of PLGA and ACC, reported that in contrast to ACC, the neoplastic luminal cells in cribriform areas of PLGA were positive for cytokeratin and integrin markers.

Skalova et al²⁰ reported a higher MIB1 (Ki-67 nuclear proliferation marker) index, in ACCs (21.4%) as compared to PLGAs (2.4%). The combination of MIB1, S-100 and Bcl-2 reportedly²¹ allows differentiation of ACC from PLGA.

Prasad et al²² compared the immunoreactivity of ACC, PLGA and canalicular adenomas with the monoclonal antibodies α -smooth muscle actin, smooth muscle myosin heavy chain and calponin and concluded that the consistently positive staining pattern in ACCs may be diagnostically useful in discriminating histologically similar but consistently negative PLGAs and canalicular adenomas. A separate study²³ reported that the anti-muscle actin antibody HHF35 stained tubular and cribriform patterns of ACC, but solid variants of ACC.

Glial fibrillary acidic protein (GFAP) is an intermediate filament cytoplasmic protein found in normal and neoplastic glial cells. Curran et al²⁴ concluded that although not all monomorphic adenomas are positive for GFAP, the presence of GFAP reactivity at the tumor/connective tissue interface is specific for monomorphic adenoma.

GFAP does not appear to be of value in discriminating between ACC and PLGA²⁵, since both of these neoplasms tend to be consistently negative for c-kit immunoreactivity²⁶.

CONCLUSION

C-kit reactivity was uniformly positive in the cytoplasm of luminal neoplastic cells in all ACCs examined. Positive reactivity was also identified in the majority of PLGAs and monomorphic adenomas. In the normal surrounding salivary gland tissue, c-kit reactivity was identified only focally in ductal epithelium.

Of potential therapeutic interest is the recent observation that the tyrosine kinase inhibitor Gleevec (Imatinib mesylate, formerly STI571, Novartis Pharmaceuticals, Switzerland) appears to be effective in the treatment of gastrointestinal stromal tumors²⁷. Gleevec inhibits the kinase activity of the normal c-Abl gene product, the oncogenic Bcr-Abl fusion protein involved in the pathogenesis of chronic myeloid leukemia, the platelet-derived growth factor receptor as well as ligand-independent c-kit phosphorylation²⁸.

Whether Gleevec will prove effective as an adjunct in treating ACCs, which generally have a very poor long-term prognosis, remains to be determined. Unlike gastrointestinal stromal tumors, in which c-kit gain-of-function mutations of the juxtamembrane domain of exon 11 are noted, and mast cell tumors, in which mutations in the tyrosine kinase domain of exon 17 have been identified, both Holst et al¹⁴ and Jeng et al¹ failed to identify similar mutations in c-kit positive salivary gland neoplasms examined. This might argue against a potential therapeutic benefit from Gleevec-based chemotherapy.

In summary, we find that in contrast to previous reports, c-kit expression was not restricted to ACC but was expressed in all three tumor types evaluated (ACC, PLGA and monomorphic adenoma). Therefore, c-kit does not appear to be an ideal marker for distinguishing between ACC and PLGA in equivocal cases, or benign from malignant salivary gland neoplasms. These markers lack the specificity required to be of routine use in daily pathology practice.

	ADENOID CYSTIC CARCINOMA	POLYMORPHOUS LOW GRADE ADENOCARCINOMA	MONOMORPHIC ADENOMA
Total number of samples	15	17	17
Negative staining	0	1	1
Weak staining (10-25% of cells)	0	4	1
Mild staining (26-50%)	1	4	1
Moderate staining (51-75%)	3	3	4
Strong staining (76-100%)	11	5	10
% samples with positive staining	100%	94%	94%

Table 1: Summary of c-kit staining results

	MAJOR SALIVARY GLAND ORIGIN	MINOR SALIVARY GLAND ORIGIN
Total number of samples	7	8
Negative staining	0	0
Weak staining (10-25% of cells)	0	0
Mild staining (26-50%)	1	0
Moderate staining (51-75%)	3	0
Strong staining (76-100%)	3	8
% samples with >75% staining	43%	100%

Table 2: Summary of c-kit staining in Adenoid Cystic Carcinoma by origin: major salivary gland versus minor salivary gland origin

Figure 1: Adenoid Cystic Carcinoma (H&E and c-kit, 200X).

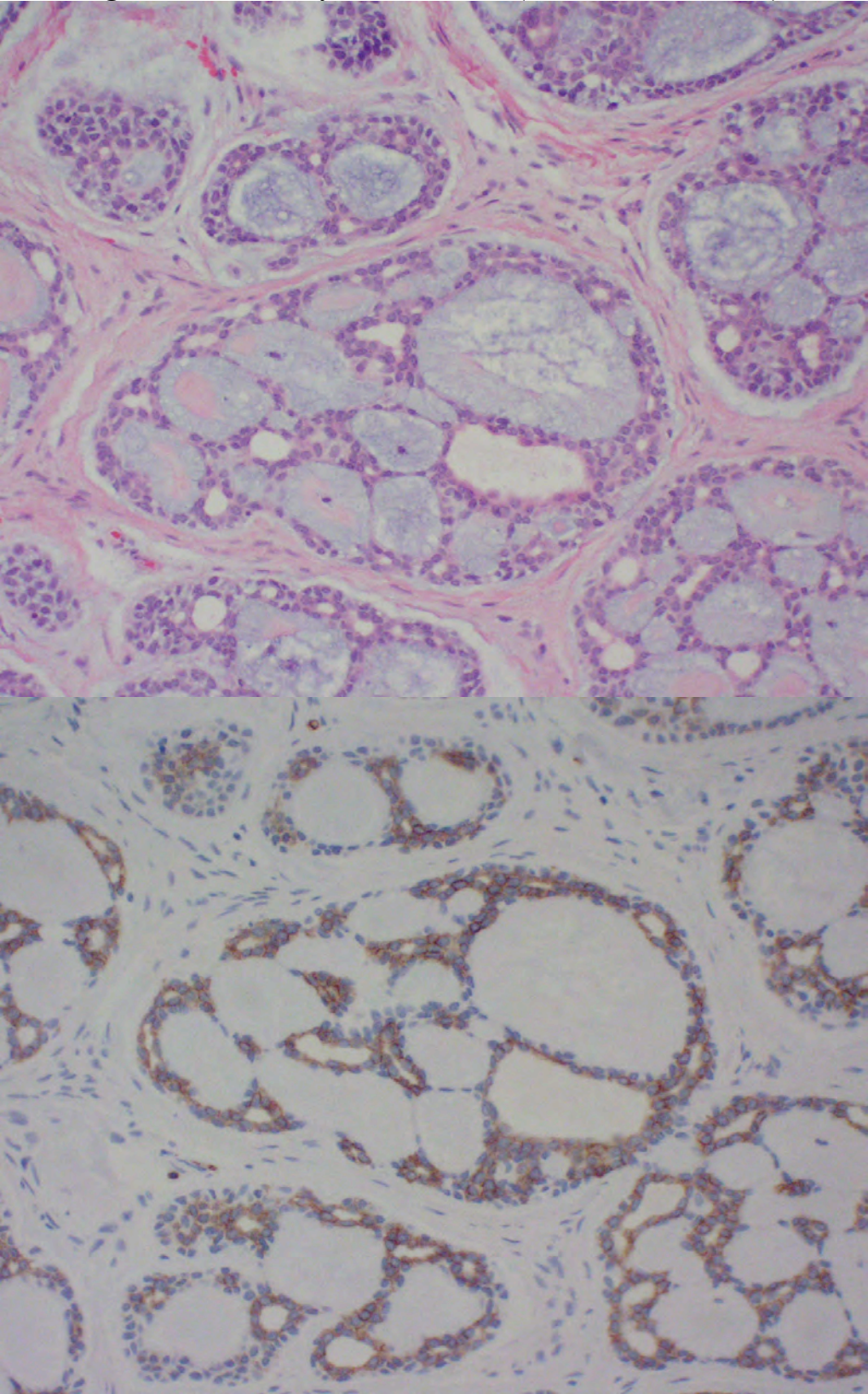


Figure 1: Adenoid Cystic Carcinoma (H&E and c-kit, 200X).

Figure 2: Polymorphous Low Grade Adenocarcinoma (H&E and c-Kit, 100X)

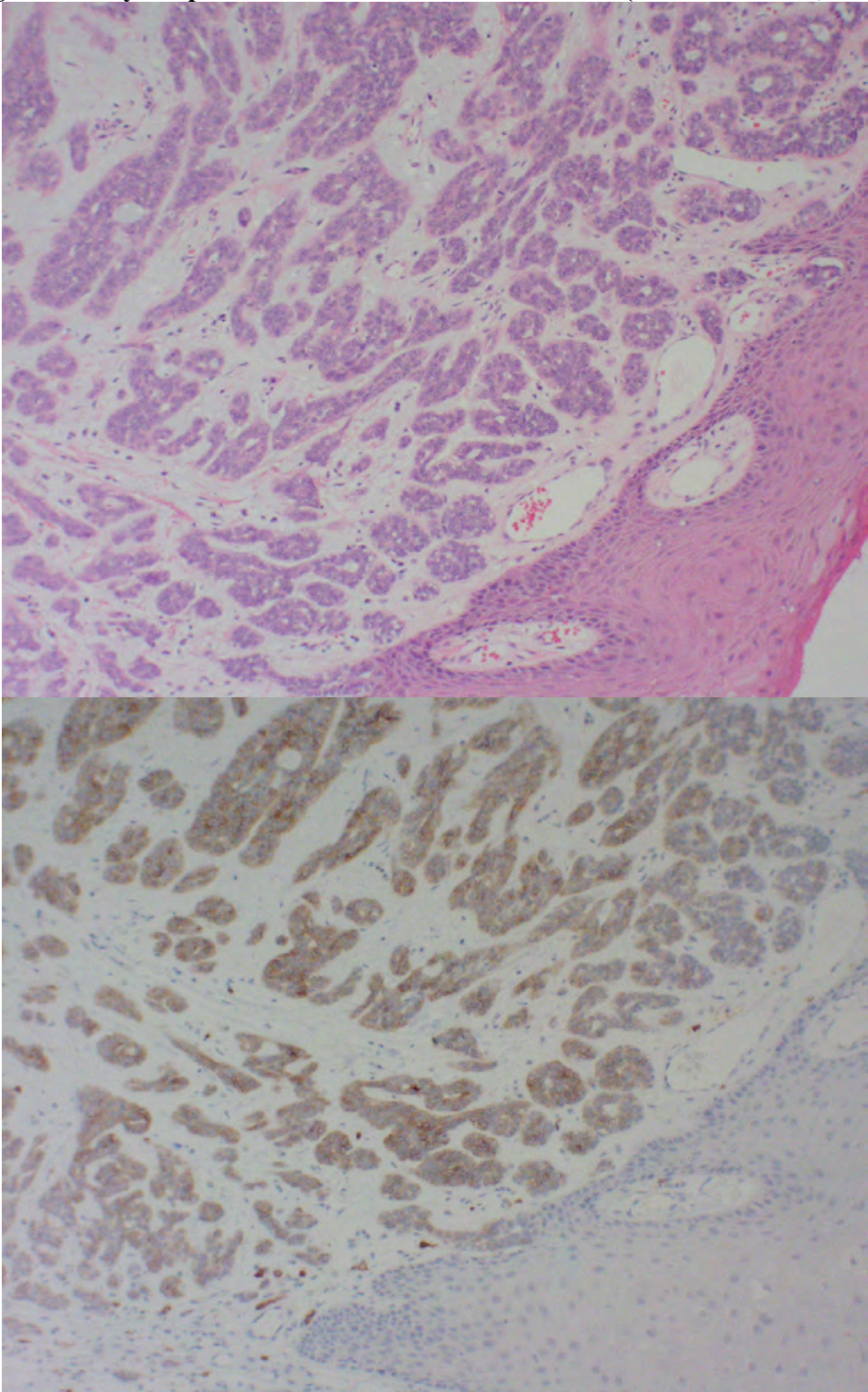


Figure 2: Polymorphous Low Grade Adenocarcinoma (H&E and c-Kit, 100X)

Figure 3: Monomorphic Adenoma (H&E and c-kit, 100X).

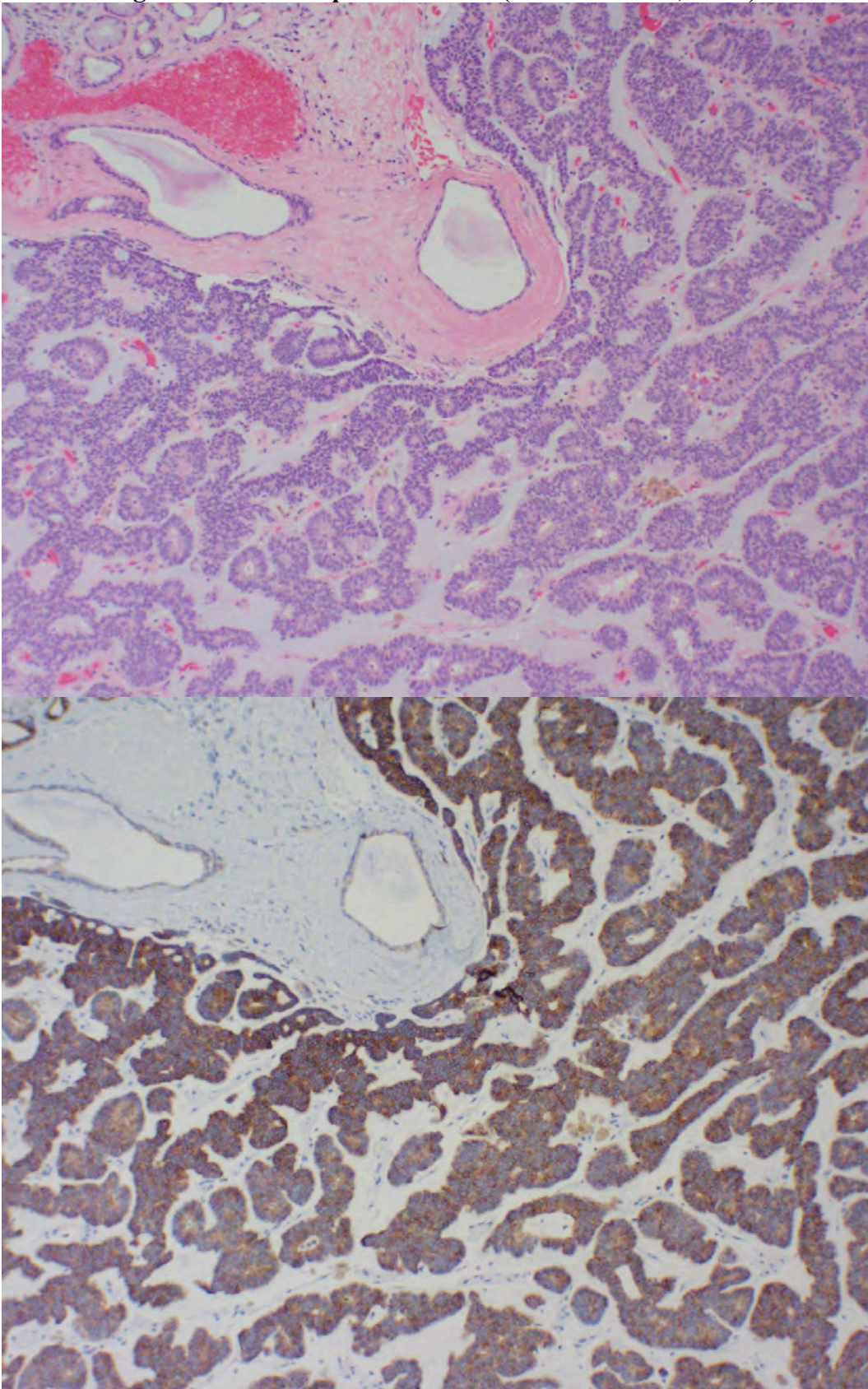


Figure 3: Monomorphic Adenoma (H&E and c-kit, 100X).

ACKNOWLEDGEMENTS

We would like to thank Dr. John E. Fantasia, D.D.S., Head, Division of Oral Pathology, Department of Dental Medicine, Long Island Jewish Medical Center, New Hyde Park, NY for his support and assistance in preparing this manuscript.

We also wish to thank Dr. Alexander Fuchs, M.D., Head, Division of Immunopathology, Department of Pathology, Long Island Jewish Medical Center, New Hyde Park, and Mr. Antonio Albert Tarectecan, HT (ASCP), Immuno-Analytical Technologist, Division of Immunopathology, Department of Pathology, Long Island Jewish Medical Center, New Hyde Park, for there assistance.

-
- ¹ Jeng Y-M, Lin C-Y, Hsu H-C. Expression of the c-kit protein is associated with certain subtypes of salivary gland carcinoma. *Cancer Letters* 2000; 154: 107-111.
 - ² Arber DA, Tamayo R, Weiss LM. Paraffin section detection of the c-kit gene product (CD117) in human tissues: Value in the diagnosis of mast cell disorders. *Human Pathol* 1998; 28: 498-504.
 - ³ Andersson J, Sjogren H, Meis-Kindblom JM, Stenman G, Aman P, Kindblom L-G. The complexity of kit gene mutations and chromosome rearrangements and their clinical correlation in gastrointestinal stromal (pacemaker) tumors. *Amer J Pathol* 2002; 160: 15-22.
 - ⁴ Graadt van Roggen JF, van Velthuysen MLF, Hogendoorn PCW. The histopathological differential diagnosis of gastrointestinal stromal tumors. *J Clin Pathol* 2001; 54: 96-102.
 - ⁵ Leroy X, Augusto D, Leteurtre E, Gosselin B. CD30 and CD117 (c-kit) used in combination are useful for distinguishing embryonal carcinoma from seminoma. *J Histochem and Cytochem* 2002; 50: 283-286.
 - ⁶ Makhlouf HR, Remotti HE, Ishak KG. Expression of kit (CD117) in angiomyolipoma. *American J Surg Path* 2002; 26: 493-497.
 - ⁷ Smithey BE, Pappo AS, Hill DA. C-kit expression in pediatric solid tumors. A comparative immunohistochemical study. *American J Surg Path* 2002; 26: 486-492.
 - ⁸ Penner CR, Cox DP, Folpe AL, Budnick S. C-kit expression distinguishes adenoid cystic carcinoma (ACC) from polymorphous low-grade adenocarcinoma (PLGA). Abstract #892: 2001 United States and Canadian Academy of Pathology Annual Meeting (New Orleans, LA).
 - ⁹ Penner CR, Folpe AL, Budnick SD. C-kit expression distinguishes salivary gland adenoid cystic carcinoma from polymorphous low-grade adenocarcinoma. *Modern Pathology* 2002; 15: 687-691.
 - ¹⁰ Ellis GL, Auclair PL. Tumors of the salivary gland. Atlas of tumor pathology. Third series. Fascicle 17. 1995. Armed Forces Institute of Pathology, Washington, DC.
 - ¹¹ Mino M, Pilch BZ, Faquin WC. Expression of c-kit in adenoid cystic carcinomas, salivary gland tumors and basaloid neoplasms of the head and neck. Abstract #930: 2002 United States and Canadian Academy of Pathology Annual Meeting (Chicago, IL).
 - ¹² Liu CZ, Keelawat S, Barnes EL. Differential expression of c-kit distinguishes salivary gland adenoid cystic carcinoma (ACC) from basal cell adenocarcinoma (BCAC). Abstract #929: 2002 United States and Canadian Academy of Pathology Annual Meeting (Chicago, IL).
 - ¹³ Oprea GM, Khalil Z, Mesa H, Manivel JC, Setty S, Pambuccian SE. Value of c-kit (CD117) staining in the differential diagnosis of basaloid tumors of the head and neck. Abstract #934: 2002 United States and Canadian Academy of Pathology Annual Meeting (Chicago, IL).
 - ¹⁴ Holst VA, Marshall CE, Moskaluk CA, Frierson HF. Kit expression and analysis of c-kit gene mutation in adenoid cystic carcinoma. *Modern Pathology* 1999; 12: 956-960.
 - ¹⁵ Oprea GM, Bachowski G, Lundeen SJ, Gulbahce HE, Coad JE, Pambuccian SE. C-kit (CD117) expression is higher in adenoid cystic carcinoma (ACC) arising in major

-
- salivary glands than in ACC arising in other locations. Abstract #93: 2002 United States and Canadian Academy of Pathology Annual Meeting (Chicago, IL).
- ¹⁶ Cohn ML, Said-Al-Naif N, Bell WC. Immunoreactivity of salivary gland tumors for CK-7, CK-20 and C-kit. Abstract #910: 2002 United States and Canadian Academy of Pathology Annual Meeting (Chicago, IL).
- ¹⁷ Hornick JL, Fletcher CDM. Immunohistochemical staining for kit (CD117) in soft tissue sarcoma is very limited in distribution. *Amer J Clin Pathol* 2002; 117: 186-193.
- ¹⁸ Simpson RHW, Clarke TJ, Sarsfield PTL, Gluckman PGC, Babajews AV. Polymorphous low-grade adenocarcinoma of the salivary glands: a clinicopathological comparison with adenoid cystic carcinoma. *Histopathology*; 1991;19: 121-129.
- ¹⁹ Araujo VC, Loducca SVL, Sousa SOM, Williams DM, Araujo NS. The cribriform features of adenoid cystic carcinoma and polymorphous low-grade adenocarcinoma: Cytokeratin and integrin expression. *Ann Diag Pathol* 2001; 5: 330-334.
- ²⁰ Skalova A, Simpson RH, Lehtonen H, Leivo I. Assessment of proliferative activity using the MIB1 antibody to help distinguish polymorphous low grade adenocarcinoma from adenoid cystic carcinoma of salivary glands. *Pathology Research and Practice* 1997; 193: 695-703.
- ²¹ R, Vargus H, Sudilovsky D, Kaplan MJ, Regezi JA. Mixed tumor, polymorphous low-grade adenocarcinoma, and adenoid cystic carcinoma of the salivary gland: Pathogenic implications and differential diagnosis by Ki-67 (MIB-1), BCL2, and S-100 immunostaining. *Modern Pathol* 1997; 10: Abstract 117A.
- ²² Prasad AR, Savera AT, Gown AM, Zarbo RJ. The myoepithelial immunophenotype in 135 benign and malignant salivary gland tumors other than pleomorphic adenoma. *Arch Pathol Lab Med* 1999; 123: 801-806.
- ²³ Araujo VC, Carvalho YR, Araujo NS. Actin versus vimentin in myoepithelial cells of salivary gland tumors: A comparative study. *Oral Surg Oral Med Oral Pathol* 1994; 77: 387-391.
- ²⁴ Curran A, Allen C, Beck F, Murrah V. Glial fibrillary acidic protein (GFAP) expression in basal cell and canalicular adenomas (BCA/CAN) vs. polymorphous low grade adenocarcinomas as an adjunct in diagnosis of morphologically similar cases. Abstract #11: 2002 American Association of Oral and Maxillofacial Pathology Annual Meeting (New Orleans, LA).
- ²⁵ Regezi JA, Zarbo RJ, Stewart JCB, Courtney RM. Polymorphous low-grade adenocarcinoma of minor salivary gland: a comparative histologic and immunohistochemical study. *Oral Surg Oral Med Oral Pathol* 1991; 71: 469-475.
- ²⁶ Curran AE, White DK, Damm DD, Murrah VA. Polymorphous low-grade adenocarcinoma versus pleomorphic adenoma of minor salivary glands: Resolution of a diagnostic dilemma by immunohistochemical analysis with glial fibrillary acidic protein. *Oral Surg Oral Med Oral Pathol Oral Radiol Endod* 2001; 91: 194-199.
- ²⁷ Joensuu H, Roberts PJ, Sarlomo-Rikala M, Andersson LC, Tervahartiala P, Tuveson D, et al. Effect of the tyrosine kinase inhibitor STI571 in a patient with a metastatic gastrointestinal stromal tumor. *New England J Medicine* 2001; 344: 1052-1056.
- ²⁸ Demetri GD. Targeting c-kit mutations in solid tumors: scientific rationale and novel therapeutic options. *Seminars in Oncology* 2001; 28: 19-26.