

Voriconazole exposure and risk of cutaneous squamous cell carcinoma among lung or hematopoietic cell transplant patients: A systematic review and meta-analysis

Short title: Voriconazole and SCC risk

Huilin Tang, MSc¹, Weilong Shi, MSc², Yiqing Song, MD, ScD¹, Jiali Han, PhD^{1,3*}

¹Department of Epidemiology, Richard M. Fairbanks School of Public Health, Indiana University, Indianapolis, Indiana, USA

²Department of Pharmacy, Peking University Third Hospital, Beijing, China

³Melvin and Bren Simon Cancer Center, Indiana University, Indianapolis, Indiana, USA

***Corresponding author:**

Jiali Han, PhD, Department of Epidemiology, Richard M. Fairbanks School of Public Health, Indiana University, 1050 Wishard Blvd, Indianapolis, Indiana, 46202, USA. Tel: +1-317-2780370, Fax: +1-317-2743443, email: jialhan@iu.edu.

Funding sources: None

Conflict of Interest: None declared

Word count of abstract: 197

Word count of capsule summary: 41

Word count of the text: 1963

Numbers of Figures/Tables: 2 figures/1 table

Numbers of supplementary figures and supplementary tables: 6 figures/3 tables

Numbers of references: 39

IRS statement: Exempted

This is the author's manuscript of the article published in final edited form as:

Tang, H., Shi, W., Song, Y., & Han, J. (2018). Voriconazole exposure and risk of cutaneous squamous cell carcinoma among lung or hematopoietic cell transplant patients: A systematic review and meta-analysis. *Journal of the American Academy of Dermatology*. <https://doi.org/10.1016/j.jaad.2018.08.010>

Registration information: None

List of attachments: MOOSE Checklist for online-only publication

Prior presentation: None

Reprint requests: Jiali Han, PhD, Department of Epidemiology, Richard M. Fairbanks School of Public Health, Indiana University, 1050 Wishard Blvd, Indianapolis, Indiana, 46202. Email: jjalhan@iu.edu.

CAPSULE SUMMARY

- Voriconazole exposure and longer duration of voriconazole were found to be significantly associated with increased risk of squamous cell carcinoma.
- Regular dermatologic surveillance should be considered for the patients taking voriconazole, especially those at high risk of developing squamous cell carcinoma.

ABSTRACT

Background: Current evidence about the association between voriconazole and risk of cutaneous squamous cell carcinoma (SCC) remains inconsistent.

Objective: To assess the association between voriconazole use and risk of SCC.

Methods: We systematically searched PubMed and Embase and performed a random effects model meta-analysis to calculate the pooled relative risk (RR) with 95% confidence interval (CI).

Results: Of the 8 studies involving 3,710 individuals with lung transplant (LT) or hematopoietic cell transplant (HCT) included in qualitative analysis, five studies were included in the meta-analysis. Use of voriconazole was significantly associated with increased risk of SCC (RR, 1.86; 95% CI, 1.36 – 2.55). The increased risk did not differ according to type of transplantation or adjustment for sun exposure. Longer duration of voriconazole was found to be positively associated with risk of SCC (RR, 1.72; 95% CI, 1.09 – 2.72). Voriconazole use was not associated with increased risk of basal cell carcinoma (RR, 0.84; 95% CI, 0.41 – 1.71).

Limitations: There were some heterogeneities in retrospective observational studies.

Conclusions: Our findings support an increased risk of SCC associated with voriconazole in individuals with LT or HCT. Routine dermatologic surveillance should be performed, especially among individuals at high risk of developing SCC.

Key words: voriconazole; squamous cell carcinoma; me; meta-analysis

INTRODUCTION

Non-melanoma skin cancer (NMSC) is the most common malignancy among individuals with solid organ transplantation¹ or hematopoietic cell transplantation (HCT).^{2, 3} The most common NMSC among this population is cutaneous squamous cell carcinoma (SCC), followed by basal cell carcinoma (BCC),¹ which together account for 95% of skin cancers in organ transplant recipients.⁴ Individuals after solid organ transplantation had a higher risk for NMSC compared to the general population,^{5, 6} and this risk increased with time after transplantation.⁷ Moreover, NMSC appears to be more aggressive among solid organ transplant recipients than in the general populations, which increases mortality among solid organ recipients.^{8, 9} Several risk factors, including history of frequent sun exposure, male sex, Fitzpatrick skin type I to III, older age at transplantation, immunotherapies, and underlying disease were found to be associated with increased risk of NMSC post-transplantation.¹⁰⁻¹⁴

Since 2002, voriconazole has been used to manage or prevent fungal infections, which are important complications after LT or HCT and can result in significant morbidity and mortality.^{15, 16} However, voriconazole can cause significant toxicity and side effects, including hepatotoxicity, visual disturbances, and photosensitivity.¹⁷ Recently, the increased risk of NMSC (primarily SCC) associated with voriconazole use attracted our attention. Voriconazole and its major hepatic metabolite, voriconazole N-oxide (VNO) may generate reactive oxygen species and induce DNA damage by sensitizing keratinocytes to ultraviolet (UV) A light.¹⁸ However, current evidence regarding the association between use of voriconazole and risk of SCC among the patients with LT and HCT remains controversial.^{7, 19-26} The conflicting results might be due to small

sample size in individual studies, heterogeneity in populations, duration or dose of voriconazole, or the use of combination treatments. We, therefore, conducted this systematic review and meta-analysis of available observational studies to critically analyze and synthesize the evidence regarding the association between use of voriconazole and risk of SCC or BCC following LT and HCT.

MATERIALS AND METHODS

The study was performed in accordance with the Meta-analysis Of Observational Studies in Epidemiology (MOOSE) guidelines for reviews of observational studies.²⁷

Search strategy and study selection

PubMed and Embase were searched from inception to September 2017 to identify eligible observational studies (**Supplemental Table 1**). Additionally, we searched the reference lists of relevant review and included studies. Two reviewers (HT and WS) selected the studies that met the following criteria: 1) observational (both prospective and retrospective) studies; 2) evaluating the association between voriconazole and risk of SCC or BCC; and 3) reporting the outcome of SCC or BCC. We included the latest study only in case of multiple reports using the same database. Conference abstracts were excluded because they offered limited information on study quality, population, and outcomes.

Data extraction and quality assessment

We collected information on study design, data source, number of participants, age (years), selection criteria, exposure definition, adjusted covariates, and outcomes of interest. Estimates on risk of SCC or BCC were extracted if appropriate. The quality of

the observational study was assessed using a 9-star scoring system as described by Newcastle-Ottawa quality-assessment scale (NOS), with total stars of 7 - 9 and 5 - 6 indicating high and moderate quality, respectively.²⁸ Two reviewers (HT and WS) independently extracted the data and assessed the quality of each study. We contacted the original author for more information if any missing information. Any disagreement was resolved by consensus or referral to a third reviewer (JH).

Statistical analysis

To account for heterogeneity between studies, a random-effects model was used to calculate the pooled relative risk (RR) and 95% confidence interval (CI) for the association between voriconazole exposure and risk of SCC or BCC. Statistical heterogeneity was quantified using the I^2 statistic (low heterogeneity: 25%, moderate heterogeneity: 50%, and high heterogeneity: 75%).²⁹ Subgroup analysis by type of transplantation or adjustment for sun/SUV exposure was performed to assess the consistency of the association between voriconazole and SCC risk. A sensitivity analysis was performed by removing one study at a time from the pooled analysis to evaluate its influence on the pooled estimate. The development of the evidence on the association between voriconazole and risk of SCC was tested by using a cumulative meta-analysis based on the date of publication. A visual inspection of the funnel plots and the Begg's and Egger's tests were applied to examine potential publication bias. All statistical analyses were performed with STATA (Version 14; Stata Corp., College Station, TX).

RESULTS

Study selection and study characteristics

Of 294 citations retrieved from electronic databases, eight observational studies involving 3,710 individuals met the eligibility criteria and were included in our systematic review (**Fig 1**). Two studies used the same database,^{21, 22} thus we included the latest study only.²² Of the eight studies included, seven were retrospective cohort studies and one was a retrospective case-control study. The characteristics and main results of the included studies are presented in **Table 1** and **Supplemental Table 2**, respectively. Four studies were assessed as high quality,^{20, 22, 24, 25} and the remaining four studies were determined to be of moderate quality.^{7, 19, 23, 26} (**Supplemental Table 3**) Six studies providing adequate data on the risk of SCC or BCC associated with voriconazole were included in the meta-analysis.

SCC risk

Eight studies involving 3,710 patients assessed the relationship between voriconazole exposure and risk of SCC.^{7, 19, 20, 22-26} Six studies were performed in individuals with LT^{7, 20, 22, 24-26} and two studies were performed in those with HCT.^{19, 23} A total of 405 SCC cases were identified among these patients, with a crude incidence of 10.9%. However, only five studies (3,122 patients with 272 SCC cases) provided relevant data on risk of SCC and were included in the meta-analysis.^{7, 19, 22, 23, 25} The overall RR for SCC risk associated with voriconazole was 1.86 (95% CI, 1.36 – 2.55), with low heterogeneity across studies ($I^2 = 4.5\%$) (**Fig 2**). Subgroup analysis by transplantation type showed a higher risk of SCC associated with voriconazole in both LT recipients (RR, 1.65; 95% CI, 1.02 – 2.68) and HCT recipients (RR, 2.29; 95% CI, 1.37 – 3.82) (**Supplemental Fig 1**). Significantly increased risk of SCC was associated with voriconazole, regardless of whether a study adjusted for sun/UV exposure (adjusted

RR: 2.42; 95% CI 1.38 – 4.22; unadjusted RR: 1.64; 95% CI 1.04 – 2.58) (**Supplemental Fig 2**).

The significant association between voriconazole and increased risk of SCC remained robust in the sensitivity analysis when each study was removed from meta-analysis at a time (**Supplemental Fig 3**). Our cumulative meta-analysis ordered by publication year indicated that the association became significant since 2017 (**Supplemental Fig 4**). There was no evidence of substantial publication bias based on the Egger's test ($P = 0.98$), Begg's test ($P = 0.81$), or visual inspection of the funnel plot (**Supplemental Fig 5**).

Dose- and duration- response analyses

Six studies evaluated the relationship between duration of voriconazole therapy and risk of SCC.^{7, 19-21, 25, 26} (**Supplemental Table 2**) Five studies found that voriconazole duration was significantly associated with the development of SCC^{19-21, 25, 26}, while one study found no such association.⁷ Meta-analysis of four studies found that longer duration of voriconazole was significantly associated with increased risk of SCC (RR, 1.72; 95% CI, 1.09 – 2.72),^{7, 19, 25, 26} while a non-significant positive association was observed in cumulative days of voriconazole use (RR, 1.74 per 180 days; 95% CI, 0.95 – 3.18) (**Supplemental Fig 6**). In addition, two studies evaluating cumulative dose and risk of SCC reported a statistically significant dose-response relationship (**Supplemental Table 2**).^{22, 25}

BCC risk

Two studies involving 41 BCC cases among 1,386 patients (crude incidence: 3.0 %) were included in the meta-analysis.^{7, 23} Neither found any association between voriconazole use and risk of BCC. The overall RR was 0.84 (95% CI, 0.41 – 1.71) (**Fig 2**).

DISCUSSION

Our meta-analysis of observational studies found that voriconazole use was significantly associated with increased risk of SCC in both LT recipients and HCT recipients. Our sensitivity analysis omitting each study, one at a time, confirmed the robustness of our results. Cumulative meta-analysis indicated that the significant increase in the risk of SCC associated with voriconazole became robust beginning in 2017. Furthermore, longer duration or higher dose of voriconazole was associated with increased risk of SCC. However, there was no significant association between voriconazole exposure and risk of BCC.

Consistent with most previous studies,^{19, 20, 22-26} our results found that voriconazole use was significantly associated with increased risk of SCC. Although the potential carcinogenic mechanisms by which voriconazole cause SCC have not been fully elucidated, it has been hypothesized that either voriconazole or VNO may facilitate UV-induced DNA damage and inhibit DNA repair.^{18, 30} Furthermore, VNO may cause phototoxicity through non-radiation related mechanisms after exposure to UVB.³¹⁻³³ Since cytochrome P450 enzymes are expressed not only in the liver but also in human keratinocytes,³⁴ an accumulation of VNO in the skin may explain our findings that longer duration and higher dose of voriconazole were independent risks for SCC.¹⁸ Sun

exposure is more strongly related to the risk of SCC than BCC.³⁵ Photosensitizing medications (e.g., diuretics) were found to be more strongly associated with SCC than BCC.³⁶ Therefore, it was not surprising that our study found no association between voriconazole and BCC, though this might also be falsely negative due to the inclusion of only two studies. In addition, it should be noted that we observed a significant increase in the risk of SCC, regardless of whether a study adjusted for sun exposure. Thus, phototoxicity may not be the sole carcinogenic pathway involved. Some studies have found that voriconazole may promote tumor development by upregulating aryl hydrocarbon receptor-dependent COX pathway,³³ and induce SCC by regulating distinct cell cycle and terminal differentiation pathways in human keratinocytes.³²

Our study systematically searched all available cohort or case-control studies on voriconazole use and risk of SCC or BCC without any restriction (e.g., language). Moreover, we fully assessed the methodological quality of the included studies and provided separate outcomes for SCC and BCC. Finally, subgroup analysis, sensitivity analysis, cumulative meta-analysis, and dose-response analysis were performed to test the robustness of our findings. Our meta-analysis had several limitations. First, the definition of voriconazole treatment varied considerably among studies, ranging from ever-exposure to at least 3 consecutive months of voriconazole therapy, which was undefined in many studies. Additionally, voriconazole was commonly used in combination with immunosuppressants in both LT recipients and HCT recipients. Immunosuppressants, especially azathioprine, were considered a strong risk factor for SCC.^{37, 38} However, several studies did not provide details of

treatment combinations so that we could not address this issue in our study. One study adjusted for immunosuppression regimen, mean cyclosporine level, and mean tacrolimus level, found a significant increase in the risk of SCC.²⁵ One included study found no association between any particular immunosuppressive medication and risk of skin cancer.⁷ Further studies are clearly warranted to explore potential interaction between voriconazole and immunosuppressive therapies on skin cancer among those patients with LT or HCT. Finally, some clinical factors, such as time since transplantation,³⁹ age at transplantation, skin type, and history of NMSC, might confound the relation between voriconazole and SCC. However, we cannot further eliminate residual confounders due to the limited number of studies included and the lack of information provided.

In summary, our systematic review and meta-analysis of 8 observational studies suggested a significant association between voriconazole use and increased risk of SCC among individuals who have undergone LT or HCT. A trend to a dose- and duration-response relationship was noted. The findings support the need for regular dermatologic surveillance for the patients taking voriconazole and also suggest taking the alternatives to voriconazole (e.g., posaconazole), especially among those already at elevated risk of SCC. Given relatively limited data, further large, high-quality studies with more detailed exposure information in terms of dose and duration of voriconazole and adequate adjustment for potential confounders (e.g., UV exposure) are required for confirmation of our findings.

Abbreviations used:

BCC: basal cell carcinoma

CI: confidence interval

HCT: hematopoietic cell transplantation

NMSC: non-melanoma skin cancer

NOS: Newcastle-Ottawa quality-assessment

RR: relative risk

SCC: squamous cell carcinoma

UV: ultraviolet

VNO: voriconazole N-oxide

REFERENCES

1. Madeleine MM, Patel NS, Plasmeijer EI et al. Epidemiology of keratinocyte carcinomas after organ transplantation. *Br J Dermatol*. 2017;177:1208-1216.
2. Omland SH, Gniadecki R, Haedersdal M, Helweg-Larsen J , Omland LH. Skin Cancer Risk in Hematopoietic Stem-Cell Transplant Recipients Compared With Background Population and Renal Transplant Recipients: A Population-Based Cohort Study. *JAMA Dermatol*. 2016;152:177-183.
3. Leisenring W, Friedman DL, Flowers ME, Schwartz JL , Deeg HJ. Nonmelanoma skin and mucosal cancers after hematopoietic cell transplantation. *J Clin Oncol*. 2006;24:1119-1126.
4. Ulrich C, Kanitakis J, Stockfleth E , Euvrard S. Skin cancer in organ transplant recipients--where do we stand today? *Am J Transplant*. 2008;8:2192-2198.
5. Zwald FO , Brown M. Skin cancer in solid organ transplant recipients: advances in therapy and management: part I. Epidemiology of skin cancer in solid organ transplant recipients. *J Am Acad Dermatol*. 2011;65:253-261; quiz 262.
6. Rizvi SMH, Aagnes B, Holdaas H et al. Long-term Change in the Risk of Skin Cancer After Organ Transplantation: A Population-Based Nationwide Cohort Study. *JAMA Dermatol*. 2017;153:1270-1277.
7. Rashtak S, Dierkhising RA, Kremers WK, Peters SG, Cassivi SD , Otley CC. Incidence and risk factors for skin cancer following lung transplantation. *J Am Acad Dermatol*. 2015;72:92-98.
8. Euvrard S, Kanitakis J , Claudy A. Skin cancers after organ transplantation. *N Engl J Med*. 2003;348:1681-1691.

9. Garrett GL, Lowenstein SE, Singer JP, He SY , Arron ST. Trends of skin cancer mortality after transplantation in the United States: 1987 to 2013. *J Am Acad Dermatol*. 2016;75:106-112.
10. Vajdic CM , van Leeuwen MT. Cancer incidence and risk factors after solid organ transplantation. *Int J Cancer*. 2009;125:1747-1754.
11. Mudigonda T, Levender MM, O'Neill JL, West CE, Pearce DJ , Feldman SR. Incidence, risk factors, and preventative management of skin cancers in organ transplant recipients: a review of single- and multicenter retrospective studies from 2006 to 2010. *Dermatol Surg*. 2013;39:345-364.
12. Garrett GL, Blanc PD, Boscardin J et al. Incidence of and Risk Factors for Skin Cancer in Organ Transplant Recipients in the United States. *JAMA Dermatol*. 2017;153:296-303.
13. Goncalves CP, Trope BM , Ramos ESM. Non-melanoma skin cancer in renal transplant recipients: a study in a Brazilian reference center. *Clin Cosmet Investig Dermatol*. 2015;8:339-344.
14. Gogia R, Binstock M, Hirose R, Boscardin WJ, Chren MM , Arron ST. Fitzpatrick skin phototype is an independent predictor of squamous cell carcinoma risk after solid organ transplantation. *J Am Acad Dermatol*. 2013;68:585-591.
15. Silveira FP , Husain S. Fungal infections in solid organ transplantation. *Med Mycol*. 2007;45:305-320.
16. Marr KA. Fungal infections in hematopoietic stem cell transplant recipients. *Med Mycol*. 2008;46:293-302.
17. Levine MT , Chandrasekar PH. Adverse effects of voriconazole: Over a decade of

use. *Clin Transplant*. 2016;30:1377-1386.

18. Ona K , Oh DH. Voriconazole N-oxide and its ultraviolet B photoproduct sensitize keratinocytes to ultraviolet A. *Br J Dermatol*. 2015;173:751-759.

19. Wojenski DJ, Bartoo GT, Merten JA et al. Voriconazole exposure and the risk of cutaneous squamous cell carcinoma in allogeneic hematopoietic stem cell transplant patients. *Transpl Infect Dis*. 2015;17:250-258.

20. Vadnerkar A, Nguyen MH, Mitsani D et al. Voriconazole exposure and geographic location are independent risk factors for squamous cell carcinoma of the skin among lung transplant recipients. *J Heart Lung Transplant*. 2010;29:1240-1244.

21. Singer JP, Boker A, Metchnikoff C et al. High cumulative dose exposure to voriconazole is associated with cutaneous squamous cell carcinoma in lung transplant recipients. *J Heart Lung Transplant*. 2012;31:694-699.

22. Mansh M, Binstock M, Williams K et al. Voriconazole Exposure and Risk of Cutaneous Squamous Cell Carcinoma, Aspergillus Colonization, Invasive Aspergillosis and Death in Lung Transplant Recipients. *Am J Transplant*. 2016;16:262-270.

23. Kuklinski LF, Li S, Karagas MR, Weng WK , Kwong BY. Effect of voriconazole on risk of nonmelanoma skin cancer after hematopoietic cell transplantation. *J Am Acad Dermatol*. 2017;77:706-712.

24. Kolaitis NA, Duffy E, Zhang A et al. Voriconazole increases the risk for cutaneous squamous cell carcinoma after lung transplantation. *Transpl Int*. 2017;30:41-48.

25. Hamandi B, Fegbeutel C, Silveira FP et al. Voriconazole and squamous cell carcinoma after lung transplantation: a multicenter study. *Am J Transplant*. 2018;18:113-124.

26. Feist A, Lee R, Osborne S, Lane J , Yung G. Increased incidence of cutaneous squamous cell carcinoma in lung transplant recipients taking long-term voriconazole. *J Heart Lung Transplant*. 2012;31:1177-1181.
27. Stroup DF, Berlin JA, Morton SC et al. Meta-analysis of observational studies in epidemiology: a proposal for reporting. Meta-analysis Of Observational Studies in Epidemiology (MOOSE) group. *JAMA*. 2000;283:2008-2012.
28. De La Cruz O , Silveira FP. Respiratory Fungal Infections in Solid Organ and Hematopoietic Stem Cell Transplantation. *Clin Chest Med*. 2017;38:727-739.
29. Higgins JP , Thompson SG. Quantifying heterogeneity in a meta-analysis. *Stat Med*. 2002;21:1539-1558.
30. Williams K, Mansh M, Chin-Hong P, Singer J , Arron ST. Voriconazole-associated cutaneous malignancy: a literature review on photocarcinogenesis in organ transplant recipients. *Clin Infect Dis*. 2014;58:997-1002.
31. Angeles JGC, Cleaver JE, Feeney L, Oh DH , Arron ST. Voriconazole does not potentiate photo damage from UVB exposure. *J Clin Exp Dermatol Res*. 2013;4:173.
32. Mansh M, Ing L, Dimon M, Celli A, Mauro TM , Arron ST. Voriconazole exposure regulates distinct cell-cycle and terminal differentiation pathways in primary human keratinocytes. *Br J Dermatol*. 2017;176:816-820.
33. Ikeya S, Sakabe JI, Yamada T , Naito T. Voriconazole-induced photocarcinogenesis is promoted by aryl hydrocarbon receptor-dependent COX-2 upregulation. *Sci Rep*. 2018;8:5050.
34. Swanson HI. Cytochrome P450 expression in human keratinocytes: an aryl hydrocarbon receptor perspective. *Chem Biol Interact*. 2004;149:69-79.

35. Armstrong BK , Kricker A. The epidemiology of UV induced skin cancer. *J Photochem Photobiol B*. 2001;63:8-18.
36. Tang H, Fu S, Zhai S, Song Y, Asgari MM , Han J. Use of antihypertensive drugs and risk of keratinocyte carcinoma: A meta-analysis of observational studies. *Pharmacoepidemiol Drug Saf*. 2018;27:279-288.
37. Jiyad Z, Olsen CM, Burke MT, Isbel NM , Green AC. Azathioprine and Risk of Skin Cancer in Organ Transplant Recipients: Systematic Review and Meta-Analysis. *Am J Transplant*. 2016;16:3490-3503.
38. Coghill AE, Johnson LG, Berg D, Resler AJ, Leca N , Madeleine MM. Immunosuppressive Medications and Squamous Cell Skin Carcinoma: Nested Case-Control Study Within the Skin Cancer after Organ Transplant (SCOT) Cohort. *Am J Transplant*. 2016;16:565-573.
39. Zwald FO, Spratt M, Lemos BD et al. Duration of voriconazole exposure: an independent risk factor for skin cancer after lung transplantation. *Dermatol Surg*. 2012;38:1369-1374.

Table 1. Characteristics of included studies

Study	Design and data source	No. of participants	Age (years)	Selection criteria	Exposure definition	Adjusted covariates
Vadnerkar et al., 2010 ²⁰	Retrospective, case-control study; University of Pittsburgh Medical Center (UPMC) between 2003 and 2008; Median follow-up: 36 months	68 LTs; SCC cases: n=17, Control: n=51	Median: Cases: 63; Control: 56	Patients with LT or heart-lung transplantation	Cumulative doses and total durations of voriconazole use obtained from the UPMC pharmacy record and Cardiothoracic Transplant database, respectively	Greater age at the time of transplant, male gender, residence in a location with high levels of sun exposure, single-lung transplant and duration and cumulative dose of voriconazole
Feist et al., 2012 ²⁶	Retrospective cohort study; University of California San Diego Health System between 2000 and 2006; Follow-up: NR	120 LTs; Voriconazole: 43 No voriconazole: 77; SCC cases:32	Mean: Voriconazole: 49.4; No voriconazole: 48.6	Single or bilateral sequential single (double) LTs	Exposed to voriconazole	NR
Rashtak et al., 2015 ⁷	Retrospective cohort study; Mayo Clinic between 1990 and 2011; Median follow-up: 3 years	166 LTs; SCC cases: 44, BCC cases: 19	Mean: 52	LT alone, heart- lung transplantation, or lung-heart-liver transplantation	NR	Univariate Cox models
Wojenski et al., 2015 ¹⁹	Retrospective cohort study; Mayo Clinic from 2007 to 2012; Follow-up: NR	381 HSCT patients; SCC cases: 27	Median: 53	Adult patients with allogeneic HSCT	Intravenous or oral voriconazole use at any time during treatment of their hematologic disease, before or after HSCT	Male gender; Transplant age; TBI conditioning; Skin cancer pre-HSCT; Chronic GVHD; photopheresis; UV therapy

Kolaitis et al., 2016 ²⁴	Retrospective cohort study; University of California at Los Angeles between 2005 and 2012; Follow-up: NR	400 LTs; SCC cases: 84	Mean: 59	Adult recipients of a first single or bilateral LT	Exposure to fungal prophylaxis was measured in two ways: (i) targeted and universal prophylaxis groups and (ii) cumulative time-dependent exposure to specific medications	Patients' age at transplant, gender, race, diagnosis, transplant type, and time-dependent cumulative AR score
Mansh et al., 2016 ²²	Retrospective cohort study; University of California at San Francisco between 1991 and 2012; Follow-up: NR	455 LTs; SCC cases: 86	Median: 55.4	Single lung, double lung, or heart-lung transplantation	Exposed to voriconazole identified using medical record review	Sex, race (White vs. Non-White) and age at transplant
Hamandi et al., 2017 ²⁵	Retrospective, cohort study; 14 LT centers across 9 countries during 2005-2008; Median follow-up: 3.51 years	900 LTs; SCC cases: 55	Median: 53	Adult patients who underwent single LT, double LT, or heart-lung transplantation	Cumulative voriconazole exposure of ≥ 30 days, not necessarily consecutive	Age, sex, immunosuppression regimen, mean cyclosporine level, mean tacrolimus level, sun exposure, history of malignancy pretransplantation, transplant rejection episodes, and underlying disease.
Kuklinski et al., 2017 ²³	Retrospective cohort study; Stanford Blood and Marrow Transplantation database between 2003 to 2015; follow-up: NR	1220 allogeneic HCTs; SCC cases: 60; BCC cases: 22	Mean: 49.2	allogeneic HCT	Use of voriconazole either before or after HCT	Older age at the time of HCT, male sex, white race, and history of NMSC; Chronic GVHD

HCT, hematopoietic cell transplant; HSCT, hematopoietic stem cell transplant; LT, lung transplant; NR, not reported; GVHD, graft-versus-host disease; COPD, chronic obstructive pulmonary disease; UV, ultraviolet

Figure legends:

Fig 1. Flow chart of the identification of eligible studies. *SCC*, squamous cell carcinoma; *BCC*, basal cell carcinoma.

Fig 2. Meta-analysis of the association between voriconazole use and risk of squamous cell carcinoma and basal cell carcinoma.

Figure 1.

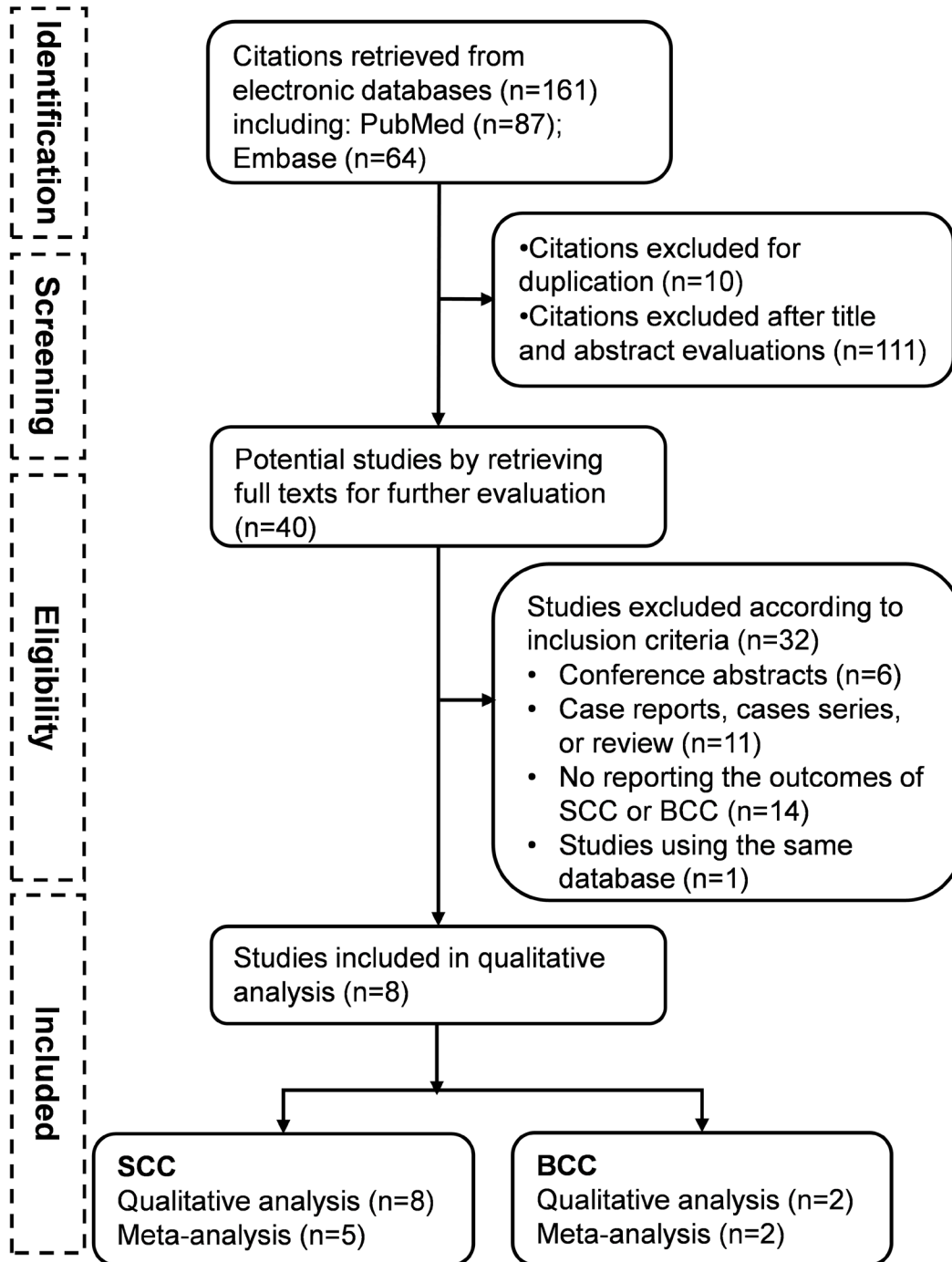


Figure 2.

