



Published in final edited form as:

Am J Orthod Dentofacial Orthop. 2015 April ; 147(4): 445–453. doi:10.1016/j.ajodo.2014.11.027.

Hounsfield Unit Change in Root and Alveolar Bone during Canine Retraction

Feifei Jiang [PhD student],

Department of Mechanical Engineering, Indiana University-Purdue University, Indianapolis, Ind

Sean Y. Liu [Assistant professor],

Department of Orthodontics and Oral Facial Genetics, Indiana University, Indianapolis, Ind

Zeyang Xia [Associate professor],

Shenzhen Institutes of Advanced Technology, Chinese Academy of Sciences and Chinese University of Hong Kong, Hong Kong, China

Shuning Li, PhD,

Department of Mechanical Engineering, Indiana University-Purdue University, Indianapolis, Ind

Jie Chen [Professor and chair],

Department of Mechanical Engineering, Indiana University-Purdue University, Indianapolis; professor, Department of Orthodontics and Oral Facial Genetics, Indiana University, Indianapolis, Ind

Katherine S. Kula [Professor and chair], and

Department of Orthodontics and Oral Facial Genetics, Indiana University, Indianapolis, Ind

George Eckert [Biostatistician Supervisor]

Department of Biostatistics, Indiana University, Indianapolis, Ind

Abstract

Objectives—The objective of this study was to determine the Hounsfield unit (HU) changes in the alveolar bone and root surface during controlled canine retractions.

Methods—Eighteen maxillary canine retraction patients were selected for this split mouth design clinical trial. The canines in each patient were randomly assigned to receive either translation or controlled tipping treatment strategy. Pre- and post-treatment cone beam computed tomography scans of each patient were used to determine tooth movement direction and HU changes. The alveolar bone and root surface were divided into 108 divisions, respectively. The HU in each division was measured. The Mixed-model ANOVA was applied to test the HU change distribution at the $p < 0.05$ significant level.

© 2014 by the American Association of Orthodontists. All rights reserved.

Reprint requests to: Jie Chen, Department of Mechanical Engineering and Department of Orthodontics and Oral Facial Genetics, Indiana University-Purdue University Indianapolis, 723 W Michigan St, SL260, Indianapolis, IN 46202. jchen3@iupui.edu.

Publisher's Disclaimer: This is a PDF file of an unedited manuscript that has been accepted for publication. As a service to our customers we are providing this early version of the manuscript. The manuscript will undergo copyediting, typesetting, and review of the resulting proof before it is published in its final citable form. Please note that during the production process errors may be discovered which could affect the content, and all legal disclaimers that apply to the journal pertain.

Results—The HU changes varied with the directions relative to the canine movement. The HU reduction occurred at the root surface. Larger reductions occurred in the divisions that were perpendicular to the moving direction. However, HU decreased in the alveolar bone in the moving direction. The highest HU reduction was at the coronal level.

Conclusions—HU reduction occurs on the root surface in the direction perpendicular to the tooth movement and in the alveolar bone in the direction of tooth movement when a canine is retracted.

Introduction

Bone modeling and remodeling are essential to orthodontic tooth movement.¹ When using mechanical forces to move the teeth with orthodontic appliances, coupled bone formation and resorption occurs on the tension and compression side of the periodontal ligament (PDL). While biological responses have been widely investigated in animal experiments,²⁻⁵ direct evidence of bone modeling and remodeling during orthodontic tooth movement in patients is still lacking.

During tooth movement, the change of mechanical environment in terms of stress and strain in PDL and bone triggers the biological reaction. On the compression side, osteoclasts are recruited and absorb the bone. On the tension side, osteoblasts are recruited, and new bone is deposited.^{6,7} Different treatment strategies introduce different stress distribution pattern in PDL. A clinical study about the effect of treatment strategy to biological response will help to understand the tooth movement mechanism.

Cone-beam computed tomography (CBCT) technology can be used for acquiring three-dimensional (3D) skeletal radiographs for dental uses.⁸ CBCT which generates lower doses of radiation than medical CT⁸ allows us to assess bone densities during orthodontic treatment. To evaluate bone remodeling on CBCT images, Hounsfield Units (HU) have been used to represent bone mineral density (BMD) and to quantify relative changes in alveolar bone.⁹ The Hounsfield scale is used to measure radiodensity in medical CT scans, which provides an accurate absolute density for bone or other tissues. Unlike medical CT, assigned HU to voxels in CBCT images are relative HU, which is affected by the surrounding tissues^{10,11} and cannot be directly used to calculate BMD values.^{9,12} In addition, Hounsfield scale varies between CBCT machines, which makes HU values incomparable between different CBCT systems.¹³ However, studies suggest that reliable HU can be obtained from serial CBCT images during orthodontic treatment using the same machine with identical scanning settings.^{14,15} With this kind of longitudinal study using subjects as their own controls, HU acquired from CBCT is reportedly highly reliable compared with medical CT and actual BMD^{9,10,13,16,17}, particularly when evaluation of their percent changes is of interest.

Reduction in BMD with decreased alveolar bone fraction was noted in both animal²⁻⁵ and human studies following tooth movement.^{14,15} Chang et al.¹⁴ suggested that maximum BMD reduction occurs along the direction of the tooth movement and Hsu et al.¹⁵ showed BMD changes along the tooth's long axis as the tooth moves. In these studies, the tooth displacement in terms of magnitude and direction was not well defined and the BMD was

checked only in scattered areas. Furthermore, HU change on the dental root surface indicating root resorption during orthodontic treatment has not been reported previously.

The aim of this prospective radiographic study was to investigate HU changes in the root and surrounding alveolar bone during canine retraction. The objectives were to determine (1) how the HU changes due to the canine retraction, and (2) whether the changes depend on the treatment strategies (i.e. translation vs. controlled tipping).

Material and methods

After Institutional Review Board approval and patient signed consents, eighteen patients (7 males and 11 females) were recruited in this prospective study. The inclusion criterion was of necessity extraction of both maxillary first premolars and maxillary canine retraction for orthodontic treatment. The average age of patients was 19 ± 9 years old (ranging from 12 to 47 years old). Prior to the study, the right and left first premolars were extracted and the upper dental arch was leveled and aligned with .019 \times .025-inch stainless steel archwire engaged in the .022 \times .028-inch slot brackets. The maxillary second molars were included in the archwire and the maxillary second premolar, first molar, and second molar were co-ligated with a .010" stainless steel wire on each side. The bilateral first molars were connected with a transpalatal arch to strengthen the anchorage. The canine retraction period varied depending on the size of initial space, appointment, and inter-patient variations. The average was 4.9 months. The canines displaced an average of 2.1 ± 1.5 mm. The canine displacement and its direction at the end of the canine retraction were determined from the CBCTs.¹⁸

For each patient, segmental T-loops were randomly assigned to the right and left canines to implement either translation (TR) or controlled tipping (CT). The T-loop delivered approximately 125 cN of closing force with predesigned moment-to-force ratio (M/F) to provide TR or CT load.¹⁹

The maxillary CBCT scans were performed on the same i-CAT 17-19 Next Generation Imaging System (Imaging Sciences i-CAT, Hatfield, PA). The field of view is 16 cm \times 13.3 cm, voxel size was 0.25 mm and the scan time was 26.9 seconds. The scans of each patient were taken immediately before and after the canine retraction. The same subject's posture with head strap and the same setting were used for all the scans.

Both CBCT images were imported by one investigator into MIMICS 13.0 (Materialise, Belgium) to reconstruct the 3D root and alveolar bone. The occlusal plane was aligned with the horizontal plane. The canine displacements were computed by overlapping the reconstructed 3D digital maxilla before and after canine retraction using the Interactive Closest Point method. The calculated tooth displacement included both tooth displacement and direction.¹⁸ The tooth movement direction was used to align the divisions characterizing the locations of HU changes. To study the HU changes, the root was segmented first. The periodontal ligament (PDL) was recognized as one voxel (0.25 mm) of radiolucency surrounding the root. The surrounding alveolar bone within two radiopaque

voxels (0.5 mm) to the PDL was formed into a bone shell. A root surface shell was then defined by eroding the PDL with two voxels. (Fig. 1)

The root surface and alveolar bone shells were divided into 3 vertical levels each with 36 circumferential divisions. In the vertical direction, the serial axial slices from the root apex to cervical enamel junction were equally divided into three levels, the apical, middle, and coronal levels. In the occlusal plane, the shells were divided into 36 divisions circumferentially around the tooth (D1 to D36). For the occlusal view, the divisions were labeled counterclockwise for the left canine and clockwise for the right canine with the division in the direction of movement (compression side) being labeled as D1. (Fig. 2) The divisions D19 on both canines were opposite to the direction of movement and subjected to tension. The divisions D2-D18 were located on the buccal side, whereas D20-D36 on the lingual side. The average value of HU of each division in each level was computed from both pre- and post-treatment CBCT scans. The changes in HU defined by the subtraction of pre-treatment HU from the post-treatment at each division were computed and plotted.

Mixed-model ANOVA was used to evaluate the effects of treatment strategy, direction of tooth movement, and divisions by different thirds on HU changes. Random effects were included for subject, subject-by-treatment, subject-by-direction, and subject-by-divisions. Means, standard errors, and 95% confidence intervals for the means were estimated using the ANOVA.

To assess repeatability of the HU measurement obtained from CBCT images, a custom designed phantom (Computerized Imaging Reference Systems, Inc. Virginia) was scanned five times using the identical CBCT settings and one investigator determined all HU measures. The phantom included 16 standardized BMD rods distributed on the dental arches with BMD ranging between 100 to 700 mg/cc. The intra-class correlation coefficient (ICC) was calculated to assess the variation and reliability.

The errors due to the segmentation process were also assessed. The process for segmenting the root surface and surrounding alveolar bone from a single CBCT scan was repeated five times. The averages and standard deviations of the HU of all directions were computed at the root surface and surrounding alveolar bone to estimate the segmentation errors and variations.

Results

Method assessment

The CBCT scans of a phantom with the same settings have negligible variation since the ICC was determined to be 0.94 between HU values of standardize BMD rods and HU values obtained from CBCT images, indicating high correlation among the scans. The segmentation error test resulted in an average error of 3.1 HU for root surface and 3.3 HU for surrounding alveolar bone, which is less than 1% of the maximum HU value. The method is adequate for this study.

HU change at root surface using the combined data from the two strategies

The average HU changes on the entire root surface due to the canine retraction are shown in Fig. 3. In general, The HU on the root surface decreased due to the treatment. Apparently, the HU reduction varies among the three levels. The division average HU was reduced by 1.7% ($\pm 11.2\%$), 2.0% ($\pm 10.1\%$), and 2.9% ($\pm 11.3\%$) at the apical, middle, and coronal level, respectively. Looking at the HU reduction in different directions, the maximum average reductions occurred in D11 and D27, which were approximately perpendicular to the direction of movement. The maximum reductions were 4.3% ($\pm 11.6\%$) in D12 and 4.3% ($\pm 11.2\%$) in D27. The most severe reduction was at the coronal level.

Without considering the level effect, the average division HU values in different color frames (in blue and red) were significantly different ($p < 0.05$), see in Fig. 3. The HU was reduced more in divisions, D10-D13 and D25-D28, than in D31-D4 and D18-D21.

Within the specific canine displacement directions, the reduction varied among the levels. Comparing the average HU values among the three levels, there were no significant differences ($p = 0.3$) observed. However, the reductions among the three levels in the directions of D11-D13 and D19-D28 were significantly different ($p < 0.05$).

Comparing HU change in root surface between the two strategies

Both strategies resulted in reduction of HU in root surface. Two treatment strategies resulted in similar HU change patterns. No divisions showed statistically significant difference between TR and CT strategies. (See in Fig. 4) There was no significant difference between the overall HU changes as well ($p = 0.32$).

At each level, the HU reductions also had no significant differences between the two strategies ($p = 0.61$ for Apical level, $p = 0.29$ for Middle level, and $p = 0.29$ for Coronal level). Considering the effects of levels on the HU within each strategy, there were no significant differences among the levels for CT ($p = 0.47$) or TR ($p = 0.24$).

HU change in surrounding alveolar bone using the combined data from the two strategies

The average HU changes in the three levels in the surrounding alveolar bone due to the canine retractions are shown in Fig. 5. The HU on the surrounding alveolar bone decreased in most directions. The average division HUs were reduced by 4.2% ($\pm 26.3\%$), 3.0% ($\pm 27.7\%$), and 11.0% ($\pm 28.5\%$) at the Apical, Middle, and Coronal levels, respectively. At each level, the maximum reductions occurred in D6 and D20, which was closely aligned to the tooth's movement direction.

The maximum reductions were 12.7% ($\pm 28.6\%$) in D6 and 12.0% ($\pm 33.7\%$) in D20. The maximum average increases occurred in D12 and D27, which were approximately perpendicular to the direction of movement. The increases were about 8.1% ($\pm 27.4\%$) in D12 and 3.1% ($\pm 25.4\%$) in D27.

Without considering the level effect, the average division HU values in different color frames were significantly different ($p < 0.05$). The HU reduced the most in D17-D22 and D35-D8 while increased in D10-D14 and D26-D28 divisions. Without considering the

division effect, there were significant differences among the levels. Coronal level obtained more reduction than Apical level ($p=0.04$) and Middle level ($p=0.01$). Considering the effect of the levels on the specific divisions, the HU reduction in the directions of D27-D3 (distal and distal-lingual region) were significantly different ($p<0.05$).

Comparing HU change in alveolar bone between the two strategies

Two treatment strategies resulted in similar HU change patterns. No divisions showed statistically significant difference between TR and CT strategies. (See Fig. 6) There was no significant difference between the overall HU changes as well ($p=0.62$). At each level, the HU changes had no significant differences between the two strategies ($p=0.91$ for Apical level, $p=0.83$ for Middle level, and $p=0.32$ for Coronal level).

However, the two sides showed some difference in comparison of the level differences individually. Considering individual treatment strategy, there were no significant differences among the levels for TR in general ($p=0.38$) while there was significant differences among the levels for CT in general ($p<0.05$). For CT, HU reduction at the Coronal level was larger than Apical level ($p=0.03$) and Middle level ($p=0.01$). The general significant level difference for CT was primarily introduced at D27-D3 ($p<0.05$, distal and distal-lingual region), with the highest reduction occurred at the Coronal level.

Discussion

This study is focused on HU changes in the alveolar bone and root surface as the canines move due to the two treatment strategies, TR and CT. The HU changes were expressed relative to the clinical tooth movement direction for the purpose of this study. The orthodontic load systems on the canines were well-controlled, with a higher moment/force on the TR side than the CT side.¹⁹ However, the resulting canine displacements varied and did not fully agree with the intended displacement pattern. Therefore, the CT and TR sides used in this study refer to the T-loop design rather than resulting clinical displacement patterns.

The primary purpose of this study was to investigate HU changes, thus only relative HU was of interest. Although using HU from the CBCT has not been considered a reliable way to quantify absolute BMD, it is still the best method available to monitor changes of BMD in terms of HU through longitudinal studies as long as the same CBCT machine and the same scan settings are used, which was validated in our repeatability test. Our study showed that the multiple scans of the same phantom with different standardized BMD rods embedded at different locations produced consistent results ($ICC = 0.94$), proving that the HU obtained from CBCT correlated well with the HU obtained from standardized BMD rods. The results are also reliable because the variation of the segmentation has been proven to be small ($<1\%$ of the maximum value).

Root

HU at the surface layer of the canine roots decreased in all divisions, indicating remodeling activities occurred on the root surface. Relatively larger reductions occurred at the divisions located closely perpendicular to the moving direction, indicating that high stress in PDL

might not be the only factor triggering the remodeling. When the canine moves, the root experiences high compressive stress in the moving direction and tensile stress on the back. The stresses in the perpendicular directions are less affected. The observation contradicts the theory that remodeling occurs at high stress areas in bone. However, the root may respond differently from bone which needs to be further investigated.

Higher HU reduction at the coronal level in the direction perpendicular to the movement direction indicates higher remodeling activities resulting in relatively less dense root surface. The mechanical environment in the area is less affected by the orthodontic load comparing to the direction of tooth movement. Thus, the area experiences less resistance to tooth movement. The HU at the apical level was reduced significantly in certain divisions (D10-D13 and D25-D28). The apex has small surface area. When its density decreases, it becomes vulnerable for surface loss, which may result in root shortening. Consistent surface density loss for a longer period of time may be the beginning of root resorption, which has been observed clinically.²⁰

Alveolar bone

HU in the surrounding alveolar bone had mixed changes. The HU of the bone decreases along the direction of tooth movement and slightly increases perpendicular to the moving direction. Contrary to the root, the maximum HU reduction occurred in the direction of tooth movement (D33-D6). The bone on the tension side also experienced significant HU reduction. The results confirmed the general finding report by Cheng et al.¹⁴ that the BMD reduces in the direction of tooth movement, but our results show less reduction. The average HU reduction (4.2% to 11.0% among levels) in alveolar bone in this study was less than the 24% reported by Chang and Hsu.^{14,15} On the other hand, HU increased in D10-14 and D26-28, which were approximately perpendicular to the moving direction. Only 2 teeth out of 144 showed increased bone density around the teeth in previous reports.^{14,15} The inconsistency could be due to the difference in treatment and analysis. In their studies, the treatment period was longer (7 month) than ours (4.9 month); the tooth displacement was shorter (non-extraction orthodontic treatments) than ours (space closure treatment). Furthermore, their studies divided the surrounding alveolar bone into three layers and only four directions, and the region studied did not cover all the surrounding alveolar bone. Generally, our results agree with the common belief that the alveolar bone remodels as the canine moves into the area in front of it and models at behind. Both modeling and remodeling will result in formation of less mineralized bone.

The HU reductions due to bone modeling or remodeling occurred with different intensity at different levels. In the moving direction (D33-D6), HU reduction at the coronal level was more severe than at apical and middle levels indicating more potential tipping. Considering the larger bony areas are in front of the root at the coronal level, the relatively less dense bone may be needed for the intended tooth movement. Contrary to root surface, the high modeling and remodeling areas in the cortical plate of the alveolar bone are experiencing higher stresses/strains due to the orthodontic movement.

Considering the effects of treatment strategy on the HU reductions, only the CT side showed significant HU reduction among the three levels in certain directions. The load on the CT

side has a relatively lower M/F, which results in a relatively higher compressive force at the Coronal level. As shown in Fig. 6, the Coronal level showed statistically significant higher HU reduction than at the Apical level, especially in the moving direction (D33-D3), which may be due to the higher compressive stress.

Treatment strategy difference did not lead to overall significant difference in the HU change distribution in the root surface or surrounding alveolar bone. Significant differences were determined only in few divisions. The results may explain the conclusion from a previous study, which showed that apical root resorption was not related to translation or tipping of the root.²¹

It is imperative for clinicians to understand the biological changes occur as a tooth moves. The rate of orthodontic tooth movement largely depends how fast the alveolar bone resorbs in the direction of tooth movement, which can be observed as changes in HU with current CBCT technologies. In the study, relative HU in the alveolar bone and on the root surface was quantified, which provides meaningful information for predicting tooth movement and potential root resorption. Furthermore, the HU changes can be used as an indicator to evaluate responses of root and surrounding bone with different clinical loading and treatment strategies.

One limitation of this study was resolution. When this clinical study was started, the highest resolution of 0.125 mm voxel size for this CBCT system was not chosen because it requires a longer scan time. Motion blur occurred even with strapping the head with each patient. Therefore, 0.25 mm voxel size was used to obtain consistently satisfactory images. This problem may be solved with the future CBCT technology with higher resolutions over a shorter period of scanning time.

Next, while the trend of bone resorption was observed with reliable HU values between CBCT scans and standardized BMD rods, it can only indicate the relative changes in bone density rather than true or absolute BMD. The HU is used to measure radiodensity and provides an accurate absolute density when using conventional medical CT. Compared to the multislice medical CT, a CBCT scanner rotates around the patient's head, obtaining nearly 600 images, and reconstructs them into 3D volumetric voxels data for visualization.²² HU values can vary depending on the relative positions in CBCT scans,²³ and the same values may not be identical from medical CT.²⁴ Nevertheless, it has recently been shown that a linear correlation can be established between HU values obtained from CBCT and medical CT scanners for different materials.²⁵ With a linear relation between the grey levels and the attenuation coefficients, it is possible to derive HU from the measured grey levels from CBCT scans.²⁶ Together with our highly reliable HU values between standardized BMD rods and HU values, the evidence explains why a clear trend of bone resorption can still be seen during orthodontic tooth movement with the same CBCT setting.

Ideally, reliable HU changes can only be quantified at the same point from serial CBCT images. In this clinical trial, both the canines and posterior teeth move and bone remodels at the same time. There were no true stationary reference points such as dental or bony structures that did not move during treatment. In order to have consistent and reliable

comparisons, the direction of tooth movement and 36 divisions were used to better understand HU changes during treatment. Despite reliable HU changes shown in this study, the accuracy and absolute changes of bone density of orthodontic tooth movement with CBCT still need to be further investigated.

Conclusion

The canine retraction resulted in HU changes on the root surface and the surrounding alveolar bone. The following specific changes are identified:

- HU distribution changed significantly in both root and alveolar bone.
- HU reduced on the surface of the roots. The maximum reduction was on the coronal level in the direction perpendicular to the direction of movement.
- HU changed in the surrounding alveolar bone. The maximum reduction was in the direction of the tooth movement and at the coronal level.
- Both TR and CT have the similar effect on the HU changes.

Acknowledgments

This research was supported by the NIH/NIDCR under grant #1R01DE018668.

References

1. Wise GE, King GJ. Mechanisms of tooth eruption and orthodontic tooth movement. *Journal of Dental Research*. 2008; 87:414–434. [PubMed: 18434571]
2. Bridges T, King G, Mohammed A. The effect of age on tooth movement and mineral density in the alveolar tissues of the rat. *American Journal of Orthodontics & Dentofacial Orthopedics*. 1988; 93:245–250. [PubMed: 3422781]
3. Verna C, Zaffe D, Siciliani G. Histomorphometric study of bone reactions during orthodontic tooth movement in rats. *Bone*. 1999; 24:371–379. [PubMed: 10221549]
4. Melsen B. Biological reaction of alveolar bone to orthodontic tooth movement. *Angle Orthod*. 1999; 69:151–158. [PubMed: 10227556]
5. Verna C, Dalstra M, Melsen B. The rate and the type of orthodontic tooth movement is influenced by bone turnover in a rat model. *Eur J Orthod*. 2000; 22:343–352. [PubMed: 11029824]
6. Roberts-Harry D, Sandy J. Orthodontics. Part 11: orthodontic tooth movement. *Br Dent J*. 2004; 196:391–394. quiz 426. [PubMed: 15071525]
7. Rody WJ Jr, King GJ, Gu G. Osteoclast recruitment to sites of compression in orthodontic tooth movement. *Am J Orthod Dentofacial Orthop*. 2001; 120:477–489. [PubMed: 11709665]
8. Schulze D, Blessmann M, Pohlenz P, Wagner KW, Heiland M. Diagnostic criteria for the detection of mandibular osteomyelitis using cone-beam computed tomography. *Dentomaxillofac Radiol*. 2006; 35:232–235. [PubMed: 16798917]
9. Nomura Y, Watanabe H, Honda E, Kurabayashi T. Reliability of voxel values from cone-beam computed tomography for dental use in evaluating bone mineral density. *Clinical Oral Implants Research*. 2010; 21:558–562. [PubMed: 20443807]
10. Araki K, Okano T. The effect of surrounding conditions on pixel value of cone beam computed tomography. *Clinical Oral Implants Research*. 2011
11. Jiang F JC. Hounsfield Units Shown in CBCT is Affected by Surrounding Tissue. *J Dent Res*. 2012; 91(Spec Iss A):918. www.dentalresearch.org.
12. Miles, DA, DR. A clinician's guide to understanding cone beam volumetric imaging (CBVI). 2007. www.ineedce.com

13. Norton MR, Gamble C. Bone classification: an objective scale of bone density using the computerized tomography scan. *Clinical Oral Implants Research*. 2001; 12:79–84. [PubMed: 11168274]
14. Chang HW, Huang HL, Yu JH, Hsu JT, Li YF, Wu YF. Effects of orthodontic tooth movement on alveolar bone density. *Clin Oral Investig*. 2012; 16:679–688.
15. Hsu JT, Chang HW, Huang HL, Yu JH, Li YF, Tu MG. Bone density changes around teeth during orthodontic treatment. *Clinical Oral Investigations*. 2011; 15:511–519. [PubMed: 20393863]
16. Mah P, Reeves TE, McDavid WD. Deriving Hounsfield units using grey levels in cone beam computed tomography. *Dento-Maxillo-Facial Radiology*. 2010; 39:323–335. [PubMed: 20729181]
17. Nomura Y, Watanabe H, Shirotu K, Honda E, Sumi Y, Kurabayshi T. Stability of voxel values from cone-beam computed tomography for dental use in evaluating bone mineral content. *Clinical Oral Implants Research*. 2012
18. Li S, Xia Z, Liu S, Eckert G, Chen J. Three-dimensional Canine Displacement Patterns in Response to Translation and Controlled Tipping Retraction Strategies. *Angle Orthodontists*. accepted 4/17/2014.
19. Xia Z, Chen J, Jiang F, Li S, Vecilli RF, Liu SY. Load system of segmental T-loops for canine retraction. *American Journal of Orthodontics & Dentofacial Orthopedics*. 2013; 144:548–556. [PubMed: 24075663]
20. Sameshima GT, Sinclair PM. Predicting and preventing root resorption: Part II. Treatment factors. *American Journal of Orthodontics & Dentofacial Orthopedics*. 2001; 119:511–515. [PubMed: 11343023]
21. Simplicio H, da Silva JS, Caldas SG, Dos Santos-Pinto A. External apical root resorption in retracted incisors. *Orthodontics (Chic)*. 2012; 13:86–93. [PubMed: 22567619]
22. Hatcher DC. Operational principles for cone-beam computed tomography. *J Am Dent Assoc*. 2010; 141(Suppl 3):3S–6S. [PubMed: 20884933]
23. Swennen GR, Schutyser F. Three-dimensional cephalometry: spiral multi-slice vs cone-beam computed tomography. *Am J Orthod Dentofacial Orthop*. 2006; 130:410–416. [PubMed: 16979502]
24. Silva IM, Freitas DQ, Ambrosano GM, Boscolo FN, Almeida SM. Bone density: comparative evaluation of Hounsfield units in multislice and cone-beam computed tomography. *Braz Oral Res*. 2012; 26:550–556. [PubMed: 23184166]
25. Mah P, Reeves TE, McDavid WD. Deriving Hounsfield units using grey levels in cone beam computed tomography. *Dentomaxillofac Radiol*. 2010; 39:323–335. [PubMed: 20729181]
26. Reeves TE, Mah P, McDavid WD. Deriving Hounsfield units using grey levels in cone beam CT: a clinical application. *Dentomaxillofac Radiol*. 2012; 41:500–508. [PubMed: 22752324]

Highlights

We studied the mineral density (MD) changes in the alveolar bone and root surface during controlled canine retractions.

The mineral density was represented by Hounsfield Unit (HU).

HU reductions occurred on the root surface in the direction perpendicular to the tooth movement.

HU reductions occurred in the alveolar bone in the direction of tooth.




Figure 1. Segmentation of the root, PDL and surrounding alveolar bone, (a) root identification, (b) formation of PDL (yellow) and alveolar bone (red) as well as the root surface (blue), and (c) alveolar bone shell (red) and root surface shell (blue)

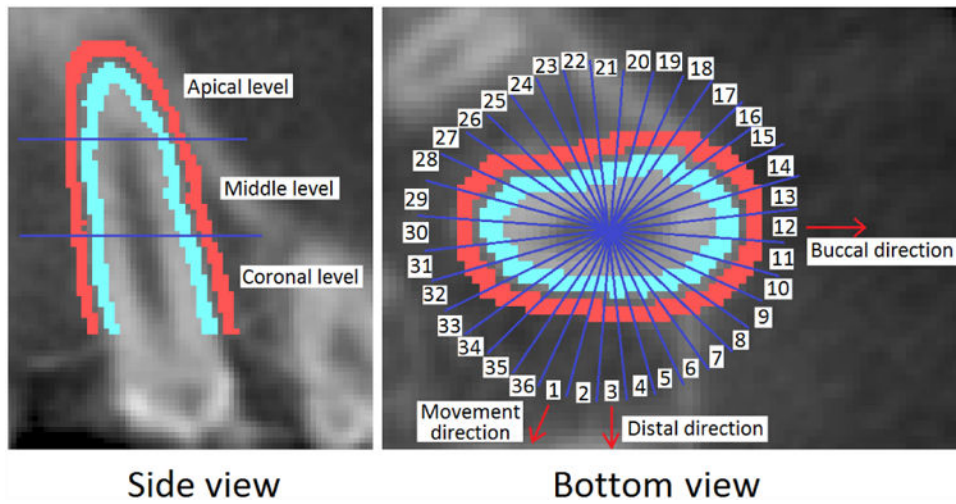


Figure 2. Formation of the root surface and alveolar bone shell and division of the 3 levels into 36 circumferential regions for the left side canine

Author Manuscript

Author Manuscript

Author Manuscript

Author Manuscript

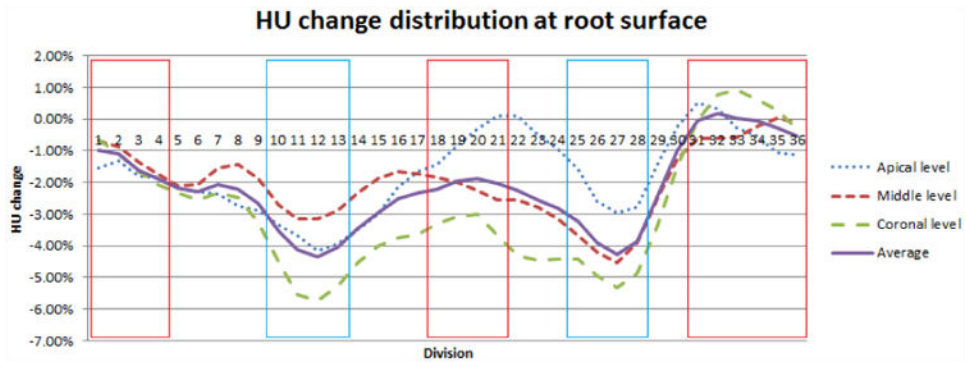


Figure 3. Average HU percent change distribution at root surface. The red frame covered the divisions in the direction of tooth movement while the blue frame covered the divisions that were perpendicular to the movement direction. The most HU reductions occurred in the directions in the blue frame.

Author Manuscript

Author Manuscript

Author Manuscript

Author Manuscript

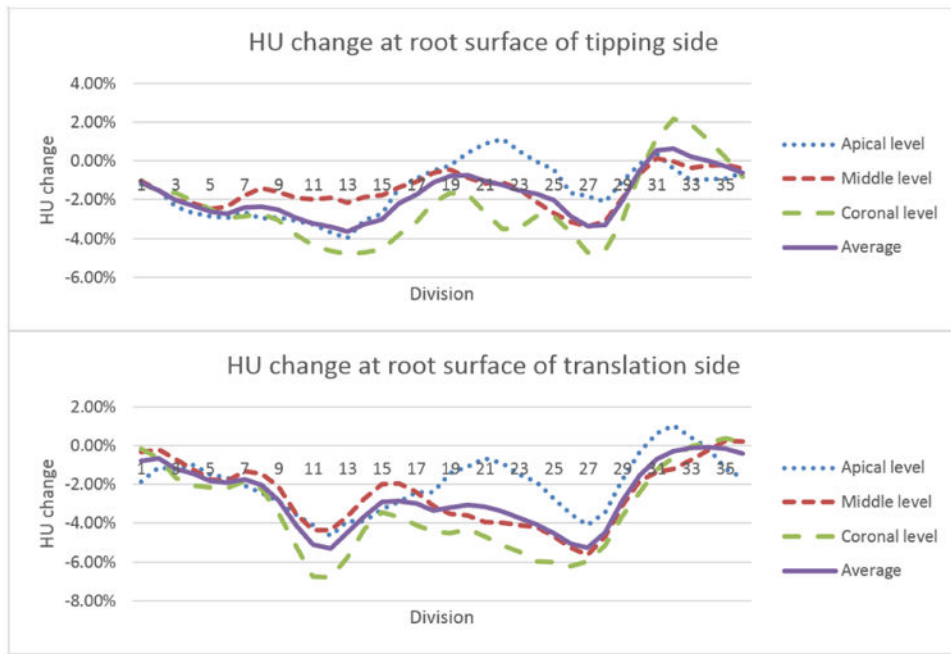


Figure 4. Comparison of average HU percent change in root boundary with treatment strategy

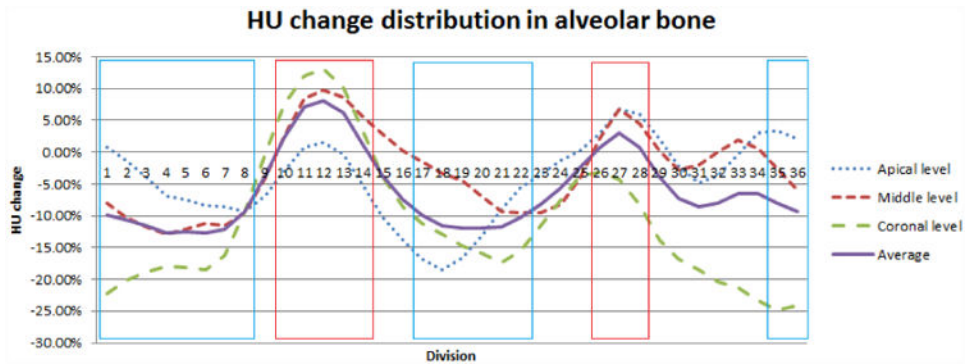


Figure 5. Average HU percent change distribution in alveolar bone. The blue frame covered the divisions in the direction of tooth movement while the red frame covered the divisions that were perpendicular to the movement direction. The most HU reductions occurred in the directions in the blue frame.

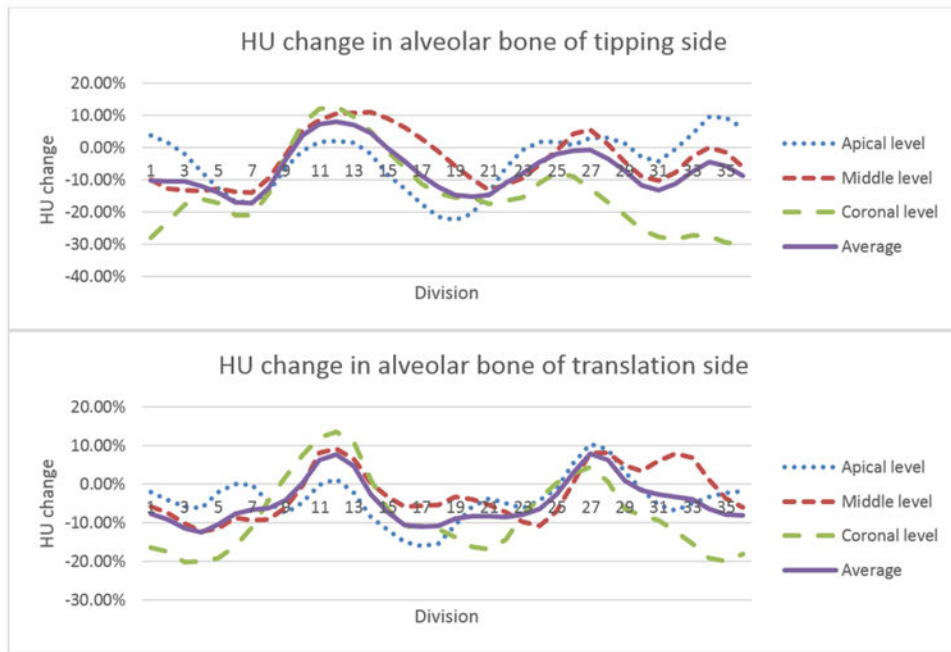


Figure 6. Comparison of average HU percent change in alveolar bone with treatment strategy