Article Type: Original Article

Title: Systematic Review and Meta-Analysis of Local Recurrence Rates of Head and Neck Cutaneous Melanomas after Wide Local Excision, Mohs Micrographic Surgery, or Staged Excision

Authors:
Peter G. Bittar, MD[1]; Julie M. Bittar, MD[2]; Jeremy R. Etzkorn, MD[3]; Jerry D. Brewer, MD, MS[4]; Leora Aizman, BS[5]; Thuzar M. Shin, MD, PhD[3]; Joseph F. Sobanko, MD[3]; Harold W. Higgins, MD[3]; Cerrene N. Giordano, MD[3]; Justine V. Cohen, DO[6]; Renee Pride, MD[4]; Marilyn T. Wan, MBChB, MPH[3]; Justin J. Leitenberger, MD[7]; Anna A. Bar, MD[7]; Sumaira Aasi, MD[8]; Jeremy S. Bordeaux, MD[9]**;** Christopher J. Miller, MD[3†]

Affiliations:
1 – Department of Dermatology, Indiana University School of Medicine; Indianapolis, IN
2 – Section of Dermatology, Rush University Medical Center; Chicago, IL
3 – Department of Dermatology, Hospital of the University of Pennsylvania; Philadelphia, PA
4 – Department of Dermatology, Mayo Clinic; Rochester, MN
5 – George Washington University School of Medicine; Washington, DC
6 – Division of Hematology and Oncology, Department of Medicine, Hospital of the University of Pennsylvania; Philadelphia, PA
7 – Department of Dermatology, Oregon Health & Science University; Portland, OR
8 – Department of Dermatology, Stanford Medicine; Stanford, CA
9 – Department of Dermatology, University Hospitals; Cleveland, OH

† – Corresponding author
Christopher J. Miller
3400 Civic Center Boulevard
Suite 1-330S
Philadelphia, PA, 19104
Phone: 215-360-0909
Fax: 215-662-4132
Email: christopher.miller@uphs.upenn.edu

Funding sources: None
Conflicts of Interest: None declared
IRB approval: None; no patient information was accessed in this study
Reprint requests: Christopher Miller

Manuscript Word Count: 2363

This is the author's manuscript of the article published in final edited form as:
Bittar, P. G., Bittar, J. M., Etzkorn, J. R., Brewer, J. D., Aizman, L., Shin, T. M., Sobanko, J. F., Higgins, H. W., Giordano, C. N., Cohen, J. V., Pride, R., Wan, M. T., Leitenberger, J. J., Bar, A. A., Aasi, S., Bordeaux, J. S., & Miller, C. J. (2021). Systematic Review and Meta-Analysis of Local Recurrence Rates of Head and Neck Cutaneous Melanomas after Wide Local Excision, Mohs Micrographic Surgery, or Staged Excision. Journal of the American Academy of Dermatology. https://doi.org/10.1016/j.jaad.2021.04.090

Abstract Word Count: 200
Capsule Summary Word Count: 50
References: 137
Figures: 4
Tables: 1
Mendeley Supplemental Material Count: 16 (available at https://data.mendeley.com/datasets/d5gkm3tk6p/1)

Keywords: General Dermatology; Dermatologic Surgery; Oncology; Melanoma; Lentigo maligna; Excision; Systematic Review; Local Recurrence; Outcomes; Head and Neck; Clinical Research; Wide local excision; Mohs Micrographic Surgery; Staged Excision; Evidence-Based Medicine

Abstract

Background: Prospective trials have not compared local recurrence rates for different excision techniques for cutaneous melanomas on the head and neck.

Objective: To determine local recurrence rates of cutaneous head and neck melanoma after wide local excision (WLE), Mohs micrographic surgery (MMS), or staged excision.

Methods: A systematic review of PubMed, EMBASE, and Web of Science identified all English case series, cohort studies and randomized controlled trials that reported local recurrence rates after surgery of cutaneous head and neck melanoma. A meta-analysis utilizing a random effects model calculated weighted local recurrence rates and confidence intervals (CI) for each surgical technique and for subgroups of MMS and staged excision.

Results: Among one-hundred manuscripts with 13,998 head and neck cutaneous melanomas, 51.0% (7138) of melanomas were treated by WLE; 34.5% (4,826) by MMS; and 14.5% (2,034) by staged excision. Local recurrence rates were lowest for MMS (0.61%; 95%CI, 0.1%-1.4%); followed by staged excision (1.8%; 95%CI, 0.1%-2.9%) and WLE (7.8%; 95%CI, 6.4%-9.3%).

Limitations: Definitions of local recurrence varied. Surgical techniques included varying proportions of invasive melanomas. Studies had heterogeneity.

Conclusion: Systematic review and meta-analysis show lower local recurrence rates for cutaneous head and neck melanoma after treatment with MMS or staged excision compared to WLE.

Capsule summary

- Prospective trials have not compared local recurrence rates for different excision techniques for cutaneous head and neck melanomas.
- Systematic review of retrospective data shows lower local recurrence rates of cutaneous head and neck melanomas after Mohs micrographic surgery or staged excision versus wide local excision.

Introduction

The purpose of melanoma excision is to prevent local recurrence and progression.[1, 2] Local recurrence may worsen prognosis,[3, 4] increase surgical costs and complexity,[5, 6] and heighten patient anxiety.[7-9] The risk for local recurrence is higher after excision of cutaneous melanomas on the head and neck,[10-12] where approximately 20% of melanomas arise.[13-17]

Although wide local excision (WLE) has been the standard technique for melanoma surgery, Mohs micrographic surgery (MMS)[18] and staged excision[19] are increasingly used to treat melanomas at high risk for local recurrence.[20] MMS and staged excision aim to lower local recurrence rates by using comprehensive microscopic margin assessment to detect and remove subclinical melanoma prior to reconstruction. Subclinical melanoma is more common for both invasive and in-situ melanomas on the head and neck.[21, 22] In its latest guidelines for cutaneous melanoma, the National Comprehensive Cancer Network indicates that comprehensive histologic assessment of margins with MMS or staged excision should be considered "for large and/or poorly defined" *in situ* or minimally invasive melanomas (<0.8 mm) associated with high cumulative sun damage.[23]

Prospective randomized controlled trials have not compared local recurrence rates after WLE versus MMS or staged excision for head and neck melanomas. We hypothesized that local recurrence rates are lower after MMS or staged excision versus WLE. This systematic review and meta-analysis evaluates published local recurrence rates after WLE, MMS, or staged excision of cutaneous head and neck melanoma.

Materials and Methods

Eligibility Criteria

A priori inclusion and exclusion criteria were established to identify studies reporting local recurrence rate after surgery of cutaneous melanoma of the head and neck. (**Mendeley Supplemental Table 1**)

Inclusion criteria were published English-language case series, cohort studies, or randomized controlled trials that specified surgical technique and reported local recurrence rates for ≥10 cutaneous head and/or neck melanomas. Mucosal melanomas were excluded. Cases were also excluded if adjuvant local treatment such as radiation, electrodessication, or imiquimod was used. No restrictions were placed on tumor depth, systemic treatment use, publication date, or follow-up time. Studies were excluded if data were duplicated in another publication. Reviews, abstracts and unpublished studies were excluded.

The primary outcome was local recurrence rate. Studies were excluded if local recurrence could not be distinguished for melanomas on the head and neck versus other locations.

Study Selection

A literature search was conducted on November 5, 2018 of PubMed, EMBASE, and Web of Science databases using search terms detailed in **Mendeley Supplemental Table 2**. Two investigators (PGB, JMB) independently reviewed all search results for inclusion and exclusion criteria. If investigators disagreed on article inclusion, they convened to reach consensus. Included studies were reviewed for references that were not captured in the search. Cohen's Kappa was calculated to provide level of inter-reviewer agreement.

Data Extraction

Two investigators (PGB, JMB) independently extracted data from included studies. Data were recorded on Microsoft Excel (Microsoft Corp., Redmond, WA). If reviewers disagreed on data, they convened to reach consensus. A third investigator (CJM) independently verified the final references and data. All three investigators (PGB, JMB, CJM) convened to resolve any disagreements.

Data Items

Extracted data included surgical technique (WLE, MMS, or staged excision); number of cutaneous head and neck melanomas; local recurrence rate; follow-up time; anatomic location; invasion status; and year(s) of surgery. Cases without follow-up information were excluded from analysis.

WLE was defined as conventional excision with microscopic margin assessment on a separate day by a dermatopathologist using formalin-fixed paraffin-embedded breadloafed sections.

MMS was defined as excision with same-day complete circumferential peripheral and deep frozen section microscopic margin assessment by the surgeon prior to reconstruction. Subcategories were: (1) MMS with immunohistochemical stains (IHC); (2) MMS without IHC; and (3) MMS with and without IHC (for series that did not segregate local recurrence for patients who were treated with versus without IHC).

Staged excision was defined as excision with microscopic margin assessment by the surgeon or dermatopathologist using formalin-fixed paraffin-embedded sections prior to reconstruction. Variations of staged excision (collarette, contour, perimeter, polygon, spaghetti, square, slow-Mohs, and mapped serial excision) were grouped into two subcategories: (1) complete peripheral microscopic margin evaluation, defined by *en face* microscopic margin

assessment of 100% of the peripheral margin; and (2) partial peripheral microscopic margin evaluation, defined by *breadloafed* sectioning to examine a portion of the peripheral margin. The central tumor's deep margin was typically evaluated with breadloafed vertical sections.

Invasion status, if specified, was classified as melanoma in situ (MIS) or invasive (extending deep to the epidermis). Invasive melanomas could not be stratified further due to inconsistent reporting of tumor depth and evolving staging criteria over time.

Data Synthesis

Statistical Analysis

The primary outcome was overall (including both MIS and invasive melanoma) local recurrence rate after WLE, MMS, or staged excision of cutaneous head and neck melanoma using a DerSimonion Laird random effects model. Subgroup analysis assessed local recurrence rates after WLE, MMS, or staged excision of MIS versus invasive melanoma. For studies reporting local recurrence rates for multiple techniques, populations for each technique were analyzed separately.

Pre-planned secondary analyses assessed local recurrence rates for subcategories of (1) MMS (with IHC; without IHC; or with and without IHC), and (2) staged excision (complete or partial peripheral microscopic margin evaluation).

Freeman-Tukey double arcsine transformation was used since some studies had local recurrence rates at or near zero.[24] Heterogeneity of local recurrence rates across studies was evaluated using Cochran's Q statistic and I^2 index. A p-value of <0.05 was considered statistically significant heterogeneity. Forest plots and calculations were generated with Open Meta.

Risk of Bias Assessment

Risk of bias in comparative studies was assessed using the ROBINS-I tool (Risk of Bias in Non-randomized Studies of Interventions).[25] This tool assesses studies across seven domains of potential bias: confounding, selection of participants, classification of interventions, deviations from intended interventions, missing data, measurement of outcomes, and selection of the reported result. In each domain, assessment focused on whether results were adjusted to account for each potential source of bias. Single-arm studies were considered at high risk of bias.

Results

Overview details

Figure 1 details the screening and selection process. Of 2197 abstracts, 100 manuscripts with 13998 head and neck cutaneous melanomas published between 1972 and 2018 were included.[18, 19, 26-123] Cohen's kappa was 0.62. According to the ROBINS-I tool, all studies (5 comparative[39, 42, 54, 85, 92] and 95 single-arm) had high-risk for bias. All included studies were either case series or cohort studies; no randomized controlled trials met inclusion criteria. Details of each manuscript are included in **Mendeley Supplemental Table 3**. **Table 1** summarizes the data for these manuscripts.

28% (28/100) of manuscripts provided a definition for local recurrence. Definitions varied from recurrence 'in the scar' (n=1);[18] 'within or adjacent to scar' (n=3);[96, 97, 101] within '2 cm' (n=7),[39, 49, 63, 69, 99, 104, 112] '3 cm' (n=1),[71] or '5 cm' (n=4) of the scar;[28, 38, 64, 102] 'at the primary/original site' (n=8);[40, 41, 46, 48, 59, 66, 73, 89] or, 'recurrence that was not nodal/regional or distal' (n=4).[58, 61, 65, 67] Details for local recurrence definitions by surgical technique are available in **Mendeley Supplemental Table 4**.

Comparison of population characteristics

The most common technique was WLE (60 references, 51.0% [7138/13998] of cases),[26-85] followed by MMS (22 references, 34.5% [4826/13998] of cases),[18, 39, 42, 54, 85-102] and staged excision (23 references, 14.5% [2034/13998] of cases).[19, 92, 103-123]

The proportion of invasive melanomas was higher in the WLE group (96% [5734/5955]) compared to MMS (30% [926/3080]) or SE (27% [416/1539]). The weighted mean follow-up time was longest for staged excision (66.5 months), followed by WLE (52.8 months) and MMS (46.9 months).

Subcategories of MMS and staged excision

Studies for MMS varied in their use of IHC. 50.0% (2411/4826) of reported patients were treated with IHC;[18, 93-98] 15.2% (732/4826) without IHC;[39, 42, 54, 86-92] and 34.9% (1683/4826) with or without IHC.[85, 99-102] Among cases treated with staged excision, 87.8% (1786/2034) were evaluated with complete[19, 103-121] and 12.2% (248/2034) with partial peripheral microscopic margins.[92, 122, 123]

Overall Local Recurrence Rates

Overall local recurrence rate was lowest for MMS (0.61% [95%CI, 0.1-1.4%]), followed by staged excision (1.8% [95%CI, 0.1-2.9%]) and WLE (7.8% [95%CI, 6.4-9.3%]). (see **Table 1** for summary data and **Figures 2-4** for forest plots)

Within MMS subcategories, local recurrence rate was 0.49% for MMS with IHC (95%CI, 0.18-0.91%); 0.20% for MMS with and without IHC (95%CI, 0.0-1.18%); and 3.37% for MMS without IHC (95%CI, 0.54-7.72%). (**Table 1** and **Mendeley Supplemental Figures 1-3)** Within staged excision subcategories, local recurrence rate was 1.7% (95%CI, 0.79-2.8%) for complete peripheral margin assessment versus 3.1% (95%CI, 3.2-7.8%) for partial peripheral margin assessment. (**Table 1** and **Mendeley Supplemental Figures 4-5**)

For overall local recurrence rates, heterogeneity was significant for studies with WLE (I^2=72.1%, p<0.0001) and MMS [all subgroups combined] (I^2=68.9%, p<0.0001) and non-significant for staged excision (I^2=20.0%, p=0.1933). For MMS subgroups, heterogeneity was significant for MMS without IHC (I^2=74.8%, p=0.0004) and MMS with and without IHC (I^2=64.0%, p=0.025) but was not significant for MMS with IHC (I^2=6.96%, p=0.37).

Local Recurrence Rates by Invasion Status

Invasion status was available for 75.5% (10574/13998) of melanomas, of which 66.9% (7076/10574) were invasive. It was not possible to distinguish local recurrence rates between MIS and invasive melanomas in some studies with mixed populations. However, local recurrence rates were determinable for 96.9% (3392/3498) of MIS and for 78.9% (5583/7076) of invasive melanomas.

For invasive melanomas, local recurrence rates were determinable for 4255 cases treated with WLE; 926 with MMS; and 402 for staged excision. For these invasive melanomas, local recurrence rate was lowest for MMS (0.61% [95%CI, 0-1.85%]) followed by staged excision (1.08% [95%CI, 0-4.04%]) and WLE (7.65% [95%CI, 5.83-9.65%]) (see **Table 1** for summary data and **Mendeley Supplemental Figures 6-8** for forest plots**)**.

For MIS, local recurrence rates were determinable for 141 cases treated with WLE; 2154 with MMS; and, 1097 with staged excision. For these MIS, local recurrence rate was lowest for MMS (0.74% [95%CI, 0.25-1.42%]) followed by staged excision (1.30% [95%CI, 0.27-2.83%]) and WLE (3.28% [95%CI, 0-10.17%]) (see **Table 1** for summary data and **Mendeley Supplemental Figure 9-11** for forest plots).

In subgroup analyses of MIS or invasive melanoma, heterogeneity was not significant for any surgical technique, except for WLE of invasive melanomas (I^2=70.2, p<0.0001). (**Table 1**)

Local Recurrence in Comparative Studies

Five studies compared two techniques. Secondary analysis of the four articles (n=341) that compared local recurrence rates after WLE versus MMS (3 articles without IHC and 1 article with and without IHC) showed that the local recurrence rate was lower for MMS with a pooled odds ratio of 0.70 (95%CI, 0.20-2.49) and heterogeneity was nonsignificant (I^2=50.15%, p=0.11).[39, 42, 54, 85] (**Mendeley Supplemental Figure 12)** However, the difference in local

recurrence rates for these comparative studies was not statistically significant (p=0.5801). Three of these four articles reported lower local recurrence rates after MMS; one reported higher local recurrence rate after MMS, but this article exclusively evaluated ear melanomas, and only 10 were treated with MMS (without IHC).[54] Analysis of MMS versus SE could not be performed, as only one study compared these techniques.[92]

Discussion

This systematic review and meta-analysis compiles the largest dataset for head and neck melanomas treated with WLE, MMS, and staged excision. These retrospective data show lower overall local recurrence rates with non-overlapping confidence intervals after treatment of cutaneous head and neck melanoma with MMS or staged excision compared to WLE. Subgroup analyses for MIS and invasive melanoma also show lower local recurrence rates after MMS or staged excision versus WLE. These retrospective data are important because current guidelines for WLE of melanoma are based on six randomized controlled trials[124-129] (n=4231 randomized cases) that included only 27 (<1%) head and neck melanomas.[130] Until prospective data are available, meta-analysis of available data provides the best method to make rational, evidence-based treatment decisions.

This study has limitations, and results should be interpreted with caution. One limitation is that the WLE cohort had a higher percentage of invasive melanomas compared to MMS or staged excision, and it was not possible to determine tumor stage or Breslow depth for all of the invasive melanomas**.** The WLE cohort may have had deeper melanomas that could have contributed to more local recurrences. However, the impact of tumor stage on local recurrence is uncertain. Whereas some studies show that higher stage melanomas have increased risk for true local[10] and local satellite/in-transit recurrence,[131, 132] others show no correlation between tumor stage and local recurrence.[12, 19] In this analysis, local recurrence rate was lower after MMS or staged excision versus WLE for head and neck melanomas whether evaluating MIS or invasive melanomas together or in subgroups. (**Table 1**)

Another limitation was missing or non-uniform definitions for local recurrence. The majority of studies did not specify criteria for local recurrence, and among the 28% (28/100) of

manuscripts that did specify criteria, definitions for local recurrence varied. Some definitions of local recurrence could include both true local recurrences and local satellite/in-transit recurrences. However, local satellite/in-transit recurrences would be unlikely to account for meaningful differences in local recurrence rates because localized intralymphatic metastasis occur with a low overall rate of 16%[131] and with an even lower rate of 2%-11% as the site of first recurrence.[131-134] In addition, local satellite/in-transit recurrences are less common for melanomas arising on the head and neck versus the extremities.[131, 134]

Another limitation was study heterogeneity, but our random effects model and sub-group analyses help minimize the effect of heterogeneity on the results. While the overall analysis showed significant heterogeneity for MMS and WLE, sub-group analysis for MIS and invasive melanomas showed non-significant heterogeneity for all techniques except WLE of invasive melanomas (I^2=70.2%, $p<0.0001$). Overall local recurrence rates were inconsistent after WLE, ranging from 0 to 46%, and exceeded 5% in two-thirds (40/60) of WLE studies. (**Figure 2**) Staged excision and MMS, particularly when performed with IHC, have lower heterogeneity and less variable local recurrence rates, possibly because microscopic-margin directed excisions are less dependent on clinical judgment.

In the absence of prospective comparative studies, meta-analysis of case series is the best available evidence to compare surgical techniques[135-137] and to guide current practice. While retrospective data have limitations, this systematic review and meta-analysis demonstrates lower local recurrence rates for cutaneous head and neck melanoma after treatment with MMS or staged excision compared to WLE.

Figure Legend

Figure 1. PRISMA Diagram of Search Process

Figure 2. Forest plots of studies of wide local excision (WLE)

Figure 3. Forest plots of studies of Mohs micrographic surgery (MMS), including studies with, without, and with and without IHC

Figure 4. Forest plots of studies of staged excision (SE), including studies with complete and partial peripheral margin assessment

Mendeley Supplemental Figure Legend

Supplemental Figure 1. Forest plot of studies of Mohs Micrographic Surgery with IHC (MMS + IHC)

Supplemental Figure 2. Forest plot of studies of Mohs Micrographic Surgery without IHC (MMS – IHC)

Supplemental Figure 3. Forest plot of studies of Mohs Micrographic Surgery with and without IHC (MMS +/- IHC)

Supplemental Figure 4. Forest plot of studies of staged excision with complete peripheral margin assessment (SE Complete)

Supplemental Figure 5. Forest plot of studies of staged excision with partial peripheral margin assessment (SE Partial)

Supplemental Figure 6. Forest plot of studies of invasive melanoma treated by wide local excision (WLE)

Supplemental Figure 7. Forest plot of studies of invasive melanoma treated by Mohs micrographic surgery (MMS), including studies with, without, and with and without IHC

Supplemental Figure 8. Forest plot of studies of invasive melanoma treated by staged excision (SE), including studies with complete and partial peripheral margin assessment

Supplemental Figure 9. Forest plot of studies of melanoma in-situ (MIS) treated by wide local excision (WLE)

Supplemental Figure 10. Forest plot of studies of melanoma in-situ (MIS) treated by Mohs micrographic surgery (MMS), including studies with, without, and with and without IHC

Supplemental Figure 11. Forest plot of studies of melanoma in-situ (MIS) treated by staged excision (SE), including studies with complete and partial peripheral margin assessment

Supplemental Figure 12. Forest plot of studies comparing Mohs micrographic surgery (MMS) to wide local excision (WLE).

Table Legend

Table 1. Summary data and local recurrence rates by technique and invasion status, results of meta-analysis

			Overall			MIS			Invasive		
Technique	**Articles, n**	**Mean F/U, mo.^**	**n**	**LR, % (CI)**	**I^2, %**	**n**	**LR, % (CI)**	**I^2, %**	**n**	**LR, % (CI)**	**I^2, %**
WLE	60	52.8	7138	7.81 (6.4-9.3)	72.1*	141	3.28 (0.0-10.2)	10.34	4255	7.65 (5.8-9.7)	70.20*
MMS	22	46.9	4826	0.61 (0.1-1.4)	68.9*	2154	0.74 (0.3-1.4)	32.89	926	0.61 (0.0-1.9)	28.49
without IHC	10	41.3	732	3.37 (0.5-7.7)	74.8*	274	1.64 (0.2-3.8)	0.00	155	2.90 (0.4-6.8)	0.00
with IHC	7	38.2	2411	0.49 (0.2-0.9)	7.0	733	0.78 (0.2-1.7)	0.00	235	0.37 (0.0-2.1)	0.00
with and without IHC	5	60.5	1683	0.20 (0.0-1.2)	64.0*	1147	0.57 (0.0-1.5)	44.66	536	0.17 (0.0-2.2)	56.02
Staged Excision	23	66.5	2034	1.84 (0.1-2.9)	20.0	1097	1.36 (0.3-2.8)	21.39	402	1.08 (0.0-4.0)	11.97
Complete	20	70.5	1786	1.68 (0.8-2.8)	18.0	1052	1.36 (0.2-3.1)	26.82	381	1.56 (0.0-5.5)	19.96
Partial	3	40.8	248	3.09 (0.3-7.8)	48.5	45	2.20 (n/a)#	n/a#	21	0 (n/a)#	n/a#
Total	100†	52.9	13998	---	---	3392	---	---	5583	---	---

WLE – Wide local excision; MMS – Mohs micrographic surgery; IHC – Immunohistochemistry; LR – Local recurrence rate; CI – 95% Confidence Interval; F/U – Follow-up; MIS – Melanoma in-situ; Complete – Complete peripheral microscopic assessment of margins; Partial – Partial peripheral microscopic assessment of margins

* statistically significant for $p<0.05$

^ The mean follow-up was weighted by number of cases in each article reporting a mean follow-up time

Only contained 1 study, so confidence interval could not be calculated

† 5 articles reported cases treated with techniques from more than one category

- The population sizes for MIS and invasive melanoma do not add up to the overall population size because it was not possible to distinguish local recurrence rates between MIS and invasive melanomas in some studies with mixed populations.

Abbreviations

CI – Confidence Interval

IHC – Immunohistochemistry

MMS – Mohs Micrographic Surgery

WLE – Wide Local Excision

References

1. Coit DG, Thompson JA, Albertini MR, Barker C, Carson WE, Contreras C et al. Cutaneous Melanoma, Version 2.2019, NCCN Clinical Practice Guidelines in Oncology. J Natl Compr Canc Netw 2019;17:367-402.

2. Swetter SM, Tsao H, Bichakjian CK, Curiel-Lewandrowski C, Elder DE, Gershenwald JE et al. Guidelines of care for the management of primary cutaneous melanoma. J Am Acad Dermatol 2019;80:208-50.

3. DeBloom JR, 2nd, Zitelli JA , Brodland DG. The invasive growth potential of residual melanoma and melanoma in situ. Dermatologic surgery : official publication for American Society for Dermatologic Surgery [et al] 2010;36:1251-7.

4. Suojarvi NJ, Jahkola TA, Virolainen S, Ilmonen SK , Hernberg MM. Outcome following local recurrence or in-transit metastases in cutaneous melanoma. Melanoma research 2012;22:447-53.

5. Etzkorn JR, Sobanko JF, Shin TM, Elenitsas R, Chu EY, Gelfand JM et al. Correlation Between Appropriate Use Criteria and the Frequency of Subclinical Spread or Reconstruction With a Flap or Graft for Melanomas Treated With Mohs Surgery With Melanoma Antigen Recognized by T Cells 1 Immunostaining. Dermatologic surgery : official publication for American Society for Dermatologic Surgery [et al] 2016;42:471-6.

6. Guy GP, Jr., Ekwueme DU, Tangka FK , Richardson LC. Melanoma treatment costs: a systematic review of the literature, 1990-2011. Am J Prev Med 2012;43:537-45.

7. Etzkorn JR, Tuttle SD, Lim I, Feit EM, Sobanko JF, Shin TM et al. Patients prioritize local recurrence risk over other attributes for surgical treatment of facial melanomas-Results of a stated preference survey and choice-based conjoint analysis. Journal of the American Academy of Dermatology 2018;79:210-9.e3.

8. Beesley VL, Smithers BM, Khosrotehrani K, Khatun M, O'Rourke P, Hughes MC et al. Supportive care needs, anxiety, depression and quality of life amongst newly diagnosed patients with localised invasive cutaneous melanoma in Queensland, Australia. Psychooncology 2015;24:763-70.

9. Beutel ME, Fischbeck S, Binder H, Blettner M, Brahler E, Emrich K et al. Depression, anxiety and quality of life in long-term survivors of malignant melanoma: a register-based cohort study. PLoS One 2015;10:e0116440.

10. Moehrle M, Kraemer A, Schippert W, Garbe C, Rassner G , Breuninger H. Clinical risk factors and prognostic significance of local recurrence in cutaneous melanoma. The British journal of dermatology 2004;151:397-406.

11. Wildemore JKt, Schuchter L, Mick R, Synnestvedt M, Elenitsas R, Bedrosian I et al. Locally recurrent malignant melanoma characteristics and outcomes: a single-institution study. Ann Plast Surg 2001;46:488-94.

12. Hudson LE, Maithel SK, Carlson GW, Rizzo M, Murray DR, Hestley AC et al. 1 or 2 cm margins of excision for T2 melanomas: do they impact recurrence or survival? Ann Surg Oncol 2013;20:346-51.

13. Al-Qurayshi Z, Hassan M, Srivastav S, Sperry S, Pagedar N, Hamner J et al. Risk and Survival of Patients with Head and Neck Cutaneous Melanoma: National Perspective. Oncology 2017;93:18-28.

14. Myers JN. Value of neck dissection in the treatment of patients with intermediate-thickness cutaneous malignant melanoma of the head and neck. Archives of otolaryngology--head & neck surgery 1999;125:110-5.

15. Lachiewicz AM, Berwick M, Wiggins CL , Thomas NE. Epidemiologic support for melanoma heterogeneity using the surveillance, epidemiology, and end results program. The Journal of investigative dermatology 2008;128:1340-2.

16. Hoersch B, Leiter U , Garbe C. Is head and neck melanoma a distinct entity? A clinical registry-based comparative study in 5702 patients with melanoma. The British journal of dermatology 2006;155:771-7.

17. Cheriyan J, Wernberg J , Urquhart A. Head and neck melanoma. The Surgical clinics of North America 2014;94:1091-113, ix.

18. Etzkorn JR, Sobanko JF, Elenitsas R, Newman JG, Goldbach H, Shin TM et al. Low recurrence rates for in situ and invasive melanomas using Mohs micrographic surgery with melanoma antigen recognized by T cells 1 (MART-1) immunostaining: Tissue processing methodology to optimize pathologic staging and margin assessment. J Am Acad Dermatol 2015;72:840-50.

19. Moyer JS, Rudy S, Boonstra PS, Kraft C, Chinn SB, Baker SR et al. Efficacy of Staged Excision With Permanent Section Margin Control for Cutaneous Head and Neck Melanoma. JAMA dermatology 2017;153:282-8.

20. Lee MP, Sobanko JF, Shin TM, Howe NM, Barbieri JS, Miller CJ et al. Evolution of Excisional Surgery Practices for Melanoma in the United States. JAMA dermatology 2019.

21. Shin TM, Shaikh WR, Etzkorn JR, Sobanko JF, Margolis DJ, Gelfand JM et al. Clinical and pathologic factors associated with subclinical spread of invasive melanoma. Journal of the American Academy of Dermatology 2017;76:714-21.

22. Shin TM, Etzkorn JR, Sobanko JF, Margolis DJ, Gelfand JM, Chu EY et al. Clinical factors associated with subclinical spread of in situ melanoma. Journal of the American Academy of Dermatology 2017;76:707-13.

23. National Comprehensive Cancer Network. Cutaneous Melanoma (Version 1.2021).

24. Nyaga VN, Arbyn M , Aerts M. Metaprop: a Stata command to perform meta-analysis of binomial data. Arch Public Health 2014;72:39.

25. Sterne J, Hernán M, McAleenan A, Reeves B , Higgins J. Chapter 25: Assessing risk of bias in a non-randomized study. In: J. Higgins, J. Thomas, J. Chandler, M. Cumpston, T. Li, M. Page, et al. editors. Cochrane Handbook for Systematic Reviews of Interventions. version 6.0 (updated July 2019): Cochrane; 2019.

26. Agnese DM, Maupin R, Tillman B, Pozderac RD, Magro C , Walker MJ. Head and neck melanoma in the sentinel lymph node era. Archives of otolaryngology--head & neck surgery 2007;133:1121-4.

27. Akhtar S, Bhat W, Magdum A , Stanley PRW. Surgical excision margins for melanoma in situ. J Plast Reconstr Aesthet Surg 2014;67:320-3.

28. Ames FC, Sugarbaker EV , Ballantyne AJ. Analysis of survival and disease control in stage I melanoma of the head and neck. American journal of surgery 1976;132:484-91.

29. Andersson AP, Dahlstrom KK , Drzewiecki KT. Prognosis of thin cutaneous head and neck melanoma (<1 mm). Eur J Surg Oncol 1996;22:55-7.

30. Andersson AP, Gottlieb J, Drzewiecki KT, Hou-Jensen K , Sondergaard K. Skin melanoma of the head and neck. Prognostic factors and recurrence-free survival in 512 patients. Cancer 1992;69:1153-6.

31. Beenken S, Byers R, Smith JL, Goepfert H , Shallenberger R. Desmoplastic melanoma. Histologic correlation with behavior and treatment. Archives of otolaryngology--head & neck surgery 1989;115:374-9.

32. Berdahl JP, Pockaj BA, Gray RJ, Casey WJ , Woog JJ. Optimal management and challenges in treatment of upper facial melanoma. Annals of plastic surgery 2006;57:616-20.

33. Bogle M, Kelly P, Shenaq J, Friedman J , Evans GRD. The role of soft tissue reconstruction after melanoma resection in the head and neck. Head Neck-J Sci Spec Head Neck 2001;23:8-15.

34. Bono A, Bartoli C, Maurichi A, Moglia D , Tragni G. Melanoma of the external ear. Tumori 1997;83:814-7.

35. Buck D, Rawlani V, Wayne J, Dumanian GA, Mustoe TA, Fine NA et al. Cosmetic outcomes following head and neck melanoma reconstruction: The patient's perspective. Can J Plast Surg 2012;20:E10-E5.

36. Byers RM, Smith L , DeWitty R. Malignant melanoma of the skin of the nose. American journal of otolaryngology 1982;3:202-3.

37. Carlson JA, Dickersin GR, Sober AJ , Barnhill RL. DESMOPLASTIC NEUROTROPIC MELANOMA - A CLINICOPATHOLOGICAL ANALYSIS OF 28 CASES. Cancer 1995;75:478-94.

38. Chen JY, Hruby G, Scolyer RA, Murali R, Hong A, FitzGerald P et al. Desmoplastic Neurotropic Melanoma A Clinicopathologic Analysis of 128 Cases. Cancer 2008;113:2770-8.

39. Chin-Lenn L, Murynka T, McKinnon JG , Arlette JP. Comparison of outcomes for malignant melanoma of the face treated using Mohs micrographic surgery and wide local excision. Dermatologic surgery : official publication for American Society for Dermatologic Surgery [et al] 2013;39:1637-45.

40. Cole DJ, Mackay GJ, Walker BF, Wooden WA, Murray DR , Coleman JJ, 3rd. Melanoma of the external ear. Journal of surgical oncology 1992;50:110-4.

41. de Langen ZJ , Vermey A. Posterolateral neck dissection. Head & neck surgery 1988;10:252-6.

42. Dika E, Fanti PA, Christman H, Piraccini BM, Misciali C, Vaccari S et al. Videodermatoscopy-assisted Mohs micrographic surgery vs. other treatments for lentigo maligna in 54 patients with a long-term follow-up. Journal of the European Academy of Dermatology and Venereology : JEADV 2016;30:1440-1.

43. Esmaeli B, Youssef A, Naderi A, Ahmadi MA, Meyer DR, McNab A et al. Margins of excision for cutaneous melanoma of the eyelid skin - The Collaborative Eyelid Skin Melanoma Group report. Ophthalmic Plast Reconstr Surg 2003;19:96-101.

44. Fisher SR, Reintgen DS , Seigler HF. Juvenile malignant melanoma of the head and neck. Laryngoscope 1988;98:184-9.

45. Frokiaer E, Kiil J , Sogaard H. The use of skin flaps in the treatment of malignant melanomas in the head and neck region. Scandinavian journal of plastic and reconstructive surgery 1982;16:157-61.

46. Gibbs P, Robinson WA, Pearlman N, Raben D, Walsh P , Gonzalez R. Management of primary cutaneous melanoma of the head and neck: The University of Colorado experience and a review of the literature. Journal of surgical oncology 2001;77:179-85; discussion 86-7.

47. Gomez-Rivera F, Santillan A, McMurphey AB, Paraskevopoulos G, Roberts DB, Prieto VG et al. Sentinel node biopsy in patients with cutaneous melanoma of the head and neck: recurrence and survival study. Head & neck 2008;30:1284-94.

48. Gyorki DE, Busam K, Panageas K, Brady MS , Coit DG. Sentinel lymph node biopsy for patients with cutaneous desmoplastic melanoma. Annals of surgical oncology 2003;10:403-7.

49. Hafström A, Romell A, Ingvar C, Wahlberg P , Greiff L. Sentinel lymph node biopsy staging for cutaneous malignant melanoma of the head and neck. Acta Oto-Laryngologica 2016;136:312-8.

50. Harish V, Bond JS, Scolyer RA, Haydu LE, Saw RP, Quinn MJ et al. Margins of excision and prognostic factors for cutaneous eyelid melanomas. Journal of plastic, reconstructive & aesthetic surgery : JPRAS 2013;66:1066-73.

51. Hudson DA, Krige JE, Grobbelaar AO, Morgan B , Grover R. Melanoma of the face: the safety of narrow excision margins. Scandinavian journal of plastic and reconstructive surgery and hand surgery 1998;32:97-104.

52. Hudson DA, Krige JE, Strover RM , King HS. Malignant melanoma of the external ear. British journal of plastic surgery 1990;43:608-11.

53. Jaber JJ, Clark JI, Muzaffar K, Ruggiero FP, Feustel PJ, Frett MJ et al. Evolving treatment strategies in thin cutaneous head and neck melanoma: 1 institution's experience. Head & neck 2011;33:7-12.

54. Jones TS, Jones EL, Gao DX, Pearlman NW, Robinson WA , McCarter M. Management of external ear melanoma: the same or something different? Am J Surg 2013;206:307-13.

55. Kane WJ, Yugueros P, Clay RP , Woods JE. Treatment outcome for 424 primary cases of clinical stage I cutaneous malignant melanoma of the head and neck. Head Neck-J Sci Spec Head Neck 1997;19:457-65.

56. Kilpatrick LA, Shen P, Stewart JH , Levine EA. Use of sentinel lymph node biopsy for melanoma of the head and neck. The American surgeon 2007;73:754-8; discussion 8-9.

57. Kukar M, Gabriel E, May R, Cho E, Lichtenthal M, Groman A et al. Conditional Survival-Based "Abbreviated" Routine Cancer Surveillance for Pathologic Stage IB Melanoma. The American surgeon 2017;83:1256-62.

58. Lang NP, Stair JM, Degges RD, Thompson C, Garner H, Baker GF et al. Melanoma today does not require radical surgery. American journal of surgery 1984;148:723-6.

59. Lent WM , Ariyan S. Flap reconstruction following wide local excision for primary malignant melanoma of the head and neck region. Annals of plastic surgery 1994;33:23-7.

60. Lin D, Kashani-Sabet M , Singer MI. Role of the head and neck surgeon in sentinel lymph node biopsy for cutaneous head and neck melanoma. Laryngoscope 2005;115:213-7.

61. Loree TR , Spiro RH. Cutaneous melanoma of the head and neck. American journal of surgery 1989;158:388-91.

62. Martini L, Brandani P, Chiarugi C , Reali UM. 1ST RECURRENCE ANALYSIS OF 840 CUTANEOUS MELANOMAS - A PROPOSAL FOR A FOLLOW-UP SCHEDULE. Tumori 1994;80:188-97.

63. McCarty MA, Lentsch EJ, Cerrati EW , Stadelmann WK. Melanoma of the ear: results of a cartilage-sparing approach to resection. European archives of oto-rhino-laryngology : official journal of the European Federation of Oto-Rhino-Laryngological Societies (EUFOS) : affiliated with the German Society for Oto-Rhino-Laryngology - Head and Neck Surgery 2013;270:2963-7.

64. McKenna DB, Lee RJ, Prescott RJ , Doherty VR. A retrospective observational study of primary cutaneous malignant melanoma patients treated with excision only compared with excision biopsy followed by wider local excision. The British journal of dermatology 2004;150:523-30.

65. Mohebati A, Ganly I, Busam KJ, Coit D, Kraus DH, Shah JP et al. The role of sentinel lymph node biopsy in the management of head and neck desmoplastic melanoma. Annals of surgical oncology 2012;19:4307-13.

66. O'Brien CJ, Coates AS, Petersen-Schaefer K, Shannon K, Thompson JF, Milton GW et al. Experience with 998 cutaneous melanomas of the head and neck over 30 years. American journal of surgery 1991;162:310-4.

67. Orr DJA, Hughes LE , Horgan K. MANAGEMENT OF MALIGNANT-MELANOMA OF THE HEAD AND NECK. Br J Surg 1993;80:998-1000.

68. Papadopoulos T, Rasiah K, Thompson JF, Quinn MJ , Crotty KA. Melanoma of the nose. The British journal of surgery 1997;84:986-9.

69. Parrett BM, Kashani-Sabet M, Leong SPL, Buncke N , Singer MI. The Safety of and Indications for Immediate Reconstruction of Head and Neck Melanoma Defects Our Early Experience. Ann Plast Surg 2014;72:S35-S7.

70. Picon AI, Coit DG, Shaha AR, Brady MS, Boyle JO, Singh BB et al. Sentinel Lymph Node Biopsy for Cutaneous Head and Neck Melanoma: Mapping the Parotid Gland. Annals of surgical oncology 2016;23:9001-9.

71. Plukker JT, Vermey A, Roodenburg JL , Oldhoff J. Posterolateral neck dissection: technique and results. The British journal of surgery 1993;80:1127-9.

72. Ravin AG, Pickett N, Johnson JL, Fisher SR, Levin LS , Seigler HF. Melanoma of the ear: treatment and survival probabilities based on 199 patients. Annals of plastic surgery 2006;57:70-6.

73. Rawlani R, Rawlani V, Qureshi HA, Kim JY , Wayne JD. Reducing margins of wide local excision in head and neck melanoma for function and cosmesis: 5-year local recurrence-free survival. Journal of surgical oncology 2015;111:795-9.

74. Rigual NR, Cheney RT, Iwenofu OH, Li Q, Loree TR, Popat SR et al. Idiosyncrasies of scalp melanoma. Laryngoscope 2007;117:1354-8.

75. Ringborg U, Afzelius LE, Lagerlof B, Adami HO, Augustsson I, Blomqvist E et al. Cutaneous malignant melanoma of the head and neck. Analysis of treatment results and prognostic factors in 581 patients: a report from the Swedish Melanoma Study Group. Cancer 1993;71:751-8.

76. Saltman BE, Ganly I, Patel SG, Coit DG, Brady MS, Wong RJ et al. Prognostic implication of sentinel lymph node biopsy in cutaneous head and neck melanoma. Head & neck 2010;32:1686-92.

77. Sekido M, Yamamoto Y, Tsutsumida A, Yoshida T, Minakawa H, Nohira K et al. Reconstructive considerations after resection of malignant melanoma in the head and neck. Scandinavian journal of plastic and reconstructive surgery and hand surgery 2005;39:222-6.

78. Shpitzer T, Gutman H, Barnea Y, Steinmetz A, Guttman D, Ad-El D et al. Sentinel node-guided evaluation of drainage patterns for melanoma of the helix of the ear. Melanoma research 2007;17:365-9.

79. Sullivan SR, Liu DZ, Mathes DW , Isik FF. Head and neck malignant melanoma: local recurrence rate following wide local excision and immediate reconstruction. Annals of plastic surgery 2012;68:33-6.

80. Urist MM, Balch CM, Soong SJ, Milton GW, Shaw HM, McGovern VJ et al. Head and neck melanoma in 534 clinical Stage I patients. A prognostic factors analysis and results of surgical treatment. Annals of surgery 1984;200:769-75.

81. Vaziri M, Buffam FV, Martinka M, Oryschak A, Dhaliwal H , White VA. Clinicopathologic features and behavior of cutaneous eyelid melanoma. Ophthalmology 2002;109:901-8.

82. Vreeburg GC, Schouwenburg PF, Hilgers FJ, de Kraker NW , Hart AA. Cutaneous melanoma of the head and neck. European journal of surgical oncology : the journal of the European Society of Surgical Oncology and the British Association of Surgical Oncology 1988;14:165-70.

83. Wanebo HJ, Cooper PH, Young DV, Harpole DH , Kaiser DL. Prognostic factors in head and neck melanoma. Effect of lesion location. Cancer 1988;62:831-7.

84. Davidsson A, Hellquist HB, Villman K , Westman G. MALIGNANT-MELANOMA OF THE EAR. J Laryngol Otol 1993;107:798-802.

85. Pockaj BA, Jaroszewski DE, DiCaudo DJ, Hentz JG, Buchel EW, Gray RJ et al. Changing surgical therapy for melanoma of the external ear. Ann Surg Oncol 2003;10:689-96.

86. Bienert TN, Trotter MJ , Arlette JP. Treatment of cutaneous melanoma of the face by Mohs micrographic surgery. J Cutan Med Surg 2003;7:25-30.

87. Mohs FE. Fixed-tissue micrographic surgery for melanoma of the ear. Archives of otolaryngology--head & neck surgery 1988;114:625-31.

88. Mohs FE, Snow SN , Larson PO. Mohs micrographic surgery fixed-tissue technique for melanoma of the nose. The Journal of dermatologic surgery and oncology 1990;16:1111-20.

89. Nosrati A, Berliner JG, Goel S, McGuire J, Morhenn V, de Souza JR et al. Outcomes of Melanoma In Situ Treated With Mohs Micrographic Surgery Compared With Wide Local Excision. JAMA dermatology 2017;153:436-41.

90. Snow SN, Mohs FE, Oriba HA, Dudley CM, Leverson G , Hetzer M. Cutaneous malignant melanoma treated by Mohs surgery. Review of the treatment results of 179 cases from the Mohs Melanoma Registry. Dermatologic surgery : official publication for American Society for Dermatologic Surgery [et al] 1997;23:1055-60.

91. Temple CL , Arlette JP. Mohs micrographic surgery in the treatment of lentigo maligna and melanoma. Journal of surgical oncology 2006;94:287-92.

92. Walling HW, Scupham RK, Bean AK , Ceilley RI. Staged excision versus Mohs micrographic surgery for lentigo maligna and lentigo maligna melanoma. J Am Acad Dermatol 2007;57:659-64.

93. Bhardwaj SS, Tope WD , Lee PK. Mohs micrographic surgery for lentigo maligna and lentigo maligna melanoma using Mel-5 immunostaining: University of Minnesota experience. Dermatologic surgery : official publication for American Society for Dermatologic Surgery [et al] 2006;32:690-6; discussion 6-7.

94. Felton S, Taylor RS , Srivastava D. Excision Margins for Melanoma In Situ on the Head and Neck. Dermatologic surgery : official publication for American Society for Dermatologic Surgery [et al] 2016;42:327-34.

95. Foxton GC, Elliott TG , Litterick KA. Treating melanoma in situ and lentigo maligna with Mohs micrographic surgery in Australia. The Australasian journal of dermatology 2019;60:33-7.

96. Newman J, Beal M, Schram SE , Lee PK. Mohs micrographic surgery for lentigo maligna and lentigo maligna melanoma using Mel-5 immunostaining: an update from the University of

Minnesota. Dermatologic surgery : official publication for American Society for Dermatologic Surgery [et al] 2013;39:1794-9.

97. Valentin-Nogueras SM, Brodland DG, Zitelli JA, Gonzalez-Sepulveda L , Nazario CM. Mohs Micrographic Surgery Using MART-1 Immunostain in the Treatment of Invasive Melanoma and Melanoma In Situ. Dermatologic surgery : official publication for American Society for Dermatologic Surgery [et al] 2016;42:733-44.

98. Zalla MJ, Lim KK, Dicaudo DJ , Gagnot MM. Mohs micrographic excision of melanoma using immunostains. Dermatologic surgery : official publication for American Society for Dermatologic Surgery [et al] 2000;26:771-84.

99. Bricca GM, Brodland DG, Ren DX , Zitelli JA. Cutaneous head and neck melanoma treated with Mohs micrographic surgery. J Am Acad Dermatol 2005;52:92-100.

100. Hou JL, Reed KB, Knudson RM, Mirzoyev SA, Lohse CM, Frohm ML et al. Five-Year Outcomes of Wide Excision and Mohs Micrographic Surgery for Primary Lentigo Maligna in an Academic Practice Cohort. Dermatol Surg 2015;41:211-8.

101. Kunishige JH, Brodland DG , Zitelli JA. Surgical margins for melanoma in situ. Journal of the American Academy of Dermatology 2012;66:438-44.

102. Zitelli JA, Brown C , Hanusa BH. Mohs micrographic surgery for the treatment of primary cutaneous melanoma. J Am Acad Dermatol 1997;37:236-45.

103. Kassi K, Vanwijck R , Kanga JM. The "collerette" technique for skin excision and biopsy: an efficient method for managing lentigo maligna of the head and neck. International journal of dermatology 2014;53:899-903.

104. Glazer ES, Porubsky CF, Francis JD, Ibanez J, Castner N, Messina JL et al. Treatment of Head and Neck Melanoma In Situ With Staged Contoured Marginal Excisions. Annals of plastic surgery 2017;78:663-7.

105. Moller MG, Pappas-Politis E, Zager JS, Santiago LA, Yu DH, Prakash A et al. Surgical Management of Melanoma-In-Situ Using a Staged Marginal and Central Excision Technique. Ann Surg Oncol 2009;16:1526-36.

106. Bosbous MW, Dzwierzynski WW , Neuburg M. Staged Excision of Lentigo Maligna and Lentigo Maligna Melanoma: A 10-Year Experience. Plast Reconstr Surg 2009;124:1947-55.

107. Clayton BD, Leshin B, Hitchcock MG, Marks M , White WL. Utility of rush paraffin-embedded tangential sections in the management of cutaneous neoplasms. Dermatologic surgery : official publication for American Society for Dermatologic Surgery [et al] 2000;26:671-8.

108. Cohen LM, McCall MW, Hodge SJ, Freedman JD, Callen JP , Zax RH. SUCCESSFUL TREATMENT OF LENTIGO-MALIGNA AND LENTIGO-MALIGNA MELANOMA WITH MOBS MICROGRAPHIC SURGERY AIDED BY RUSH PERMANENT SECTIONS. Cancer 1994;73:2964-70.

109. Jahn V, Breuninger H, Garbe C, Maassen MM , Moehrle M. Melanoma of the nose: prognostic factors, three-dimensional histology, and surgical strategies. Laryngoscope 2006;116:1204-11.

110. Lee MR , Ryman WJ. Treatment of lentigo maligna with total circumferential margin control using vertical and horizontal permanent sections: a retrospective study. The Australasian journal of dermatology 2008;49:196-201.

111. Mahoney EJ, Dolan RW, Choi EE , Olbricht SM. Surgical reconstruction of lentigo maligna defects. Arch Facial Plast Surg 2005;7:342-6.

112. Then SY, Malhotra R, Barlow R, Kurwa H, Huilgol S, Joshi N et al. Early cure rates with narrow-margin slow-Mohs surgery for periocular malignant melanoma. Dermatologic surgery : official publication for American Society for Dermatologic Surgery [et al] 2009;35:17-23.

113. Agarwal-Antal N, Bowen GM , Gerwels JW. Histologic evaluation of lentigo maligna with permanent sections: Implications regarding current guidelines. J Am Acad Dermatol 2002;47:743-8.

114. Abdelmalek M, Loosemore MP, Hurt MA , Hruza G. Geometric staged excision for the treatment of lentigo maligna and lentigo maligna melanoma: a long-term experience with literature review. Archives of dermatology 2012;148:599-604.

115. Mahoney MH, Joseph M , Temple CL. The perimeter technique for lentigo maligna: an alternative to Mohs micrographic surgery. Journal of surgical oncology 2005;91:120-5.

116. Shumaker PR, Kelley B, Swann MH , Greenway HT, Jr. Modified Mohs micrographic surgery for periocular melanoma and melanoma in situ: long-term experience at Scripps Clinic. Dermatologic surgery : official publication for American Society for Dermatologic Surgery [et al] 2009;35:1263-70.

117. Champin J, Perrot JL, Cinotti E, Labeille B, Douchet C, Parrau G et al. In vivo reflectance confocal microscopy to optimize the spaghetti technique for defining surgical margins of lentigo maligna. Dermatologic surgery : official publication for American Society for Dermatologic Surgery [et al] 2014;40:247-56.

118. Gaudy-Marqueste C, Perchenet AS, Tasei AM, Madjlessi N, Magalon G, Richard MA et al. The "spaghetti technique": an alternative to Mohs surgery or staged surgery for problematic lentiginous melanoma (lentigo maligna and acral lentiginous melanoma). Journal of the American Academy of Dermatology 2011;64:113-8.

119. Demirci H, Johnson TM, Frueh BR, Musch DC, Fullen DR , Nelson CC. Management of periocular cutaneous melanoma with a staged excision technique and permanent sections the square procedure. Ophthalmology 2008;115:2295-300.e3.

120. Jejurikar SS, Borschel GH, Johnson TM, Lowe L , Brown DL. Immediate, optimal reconstruction of facial lentigo maligna and melanoma following total peripheral margin control. Plastic and reconstructive surgery 2007;120:1249-55.

121. Patel AN, Perkins W, Leach IH , Varma S. Johnson square procedure for lentigo maligna and lentigo maligna melanoma. Clinical and experimental dermatology 2014;39:570-6.

122. Hill DC , Gramp AA. Surgical treatment of lentigo maligna and lentigo maligna melanoma. The Australasian journal of dermatology 1999;40:25-30.

123. Huilgol SC, Selva D, Chen C, Hill DC, James CL, Gramp A et al. Surgical margins for lentigo maligna and lentigo maligna melanoma - The technique of mapped serial excision. Arch Dermatol 2004;140:1087-+.

124. Balch CM, Soong SJ, Smith T, Ross MI, Urist MM, Karakousis CP et al. Long-term results of a prospective surgical trial comparing 2 cm vs. 4 cm excision margins for 740 patients with 1-4 mm melanomas. Annals of surgical oncology 2001;8:101-8.

125. Cohn-Cedermark G, Rutqvist LE, Andersson R, Breivald M, Ingvar C, Johansson H et al. Long term results of a randomized study by the Swedish Melanoma Study Group on 2-cm versus 5-cm resection margins for patients with cutaneous melanoma with a tumor thickness of 0.8-2.0 mm. Cancer 2000;89:1495-501.

126. Gillgren P, Drzewiecki KT, Niin M, Gullestad HP, Hellborg H, Månsson-Brahme E et al. 2-cm versus 4-cm surgical excision margins for primary cutaneous melanoma thicker than 2 mm: a randomised, multicentre trial. Lancet 2011;378:1635-42.

127. Khayat D, Rixe O, Martin G, Soubrane C, Banzet M, Bazex JA et al. Surgical margins in cutaneous melanoma (2 cm versus 5 cm for lesions measuring less than 2.1-mm thick). Cancer 2003;97:1941-6.

128. Thomas JM, Newton-Bishop J, A'Hern R, Coombes G, Timmons M, Evans J et al. Excision margins in high-risk malignant melanoma. N Engl J Med 2004;350:757-66.

129. Veronesi U , Cascinelli N. Narrow excision (1-cm margin). A safe procedure for thin cutaneous melanoma. Arch Surg 1991;126:438-41.

130. Rzepecki AK, Hwang CD, Etzkorn JR, Shin TM, Sobanko JF, Howe NM et al. The "Rule of 10s" versus the "Rule of 2s": High complication rates after conventional excision with postoperative margin assessment of specialty site versus trunk and proximal extremity melanomas. Journal of the American Academy of Dermatology 2018.

131. Kretschmer L, Beckmann I, Thoms KM, Mitteldorf C, Bertsch HP , Neumann C. Factors predicting the risk of in-transit recurrence after sentinel lymphonodectomy in patients with cutaneous malignant melanoma. Annals of surgical oncology 2006;13:1105-12.

132. Stucky CC, Gray RJ, Dueck AC, Wasif N, Laman SD, Sekulic A et al. Risk factors associated with local and in-transit recurrence of cutaneous melanoma. American journal of surgery 2010;200:770-4; discussion 4-5.

133. Gonzalez AB, Baum CL, Brewer JD, Arpey CJ, Harmsen WS, Suman VJ et al. Patterns of failure following the excision of in-transit lesions in melanoma and the influence of excisional margins. Journal of surgical oncology 2018;118:606-13.

134. Tie EN, Henderson MA , Gyorki DE. Management of in-transit melanoma metastases: a review. ANZ J Surg 2019;89:647-52.

135. Chambers D, Rodgers M , Woolacott N. Not only randomized controlled trials, but also case series should be considered in systematic reviews of rapidly developing technologies. J Clin Epidemiol 2009;62:1253-60.e4.

136. Murad MH, Sultan S, Haffar S , Bazerbachi F. Methodological quality and synthesis of case series and case reports. BMJ Evid Based Med 2018;23:60-3.

137. Naik HB , Abuabara K. Systematic reviews of case reports and case series: from anecdote to evidence. The British journal of dermatology 2018;178:317-8.

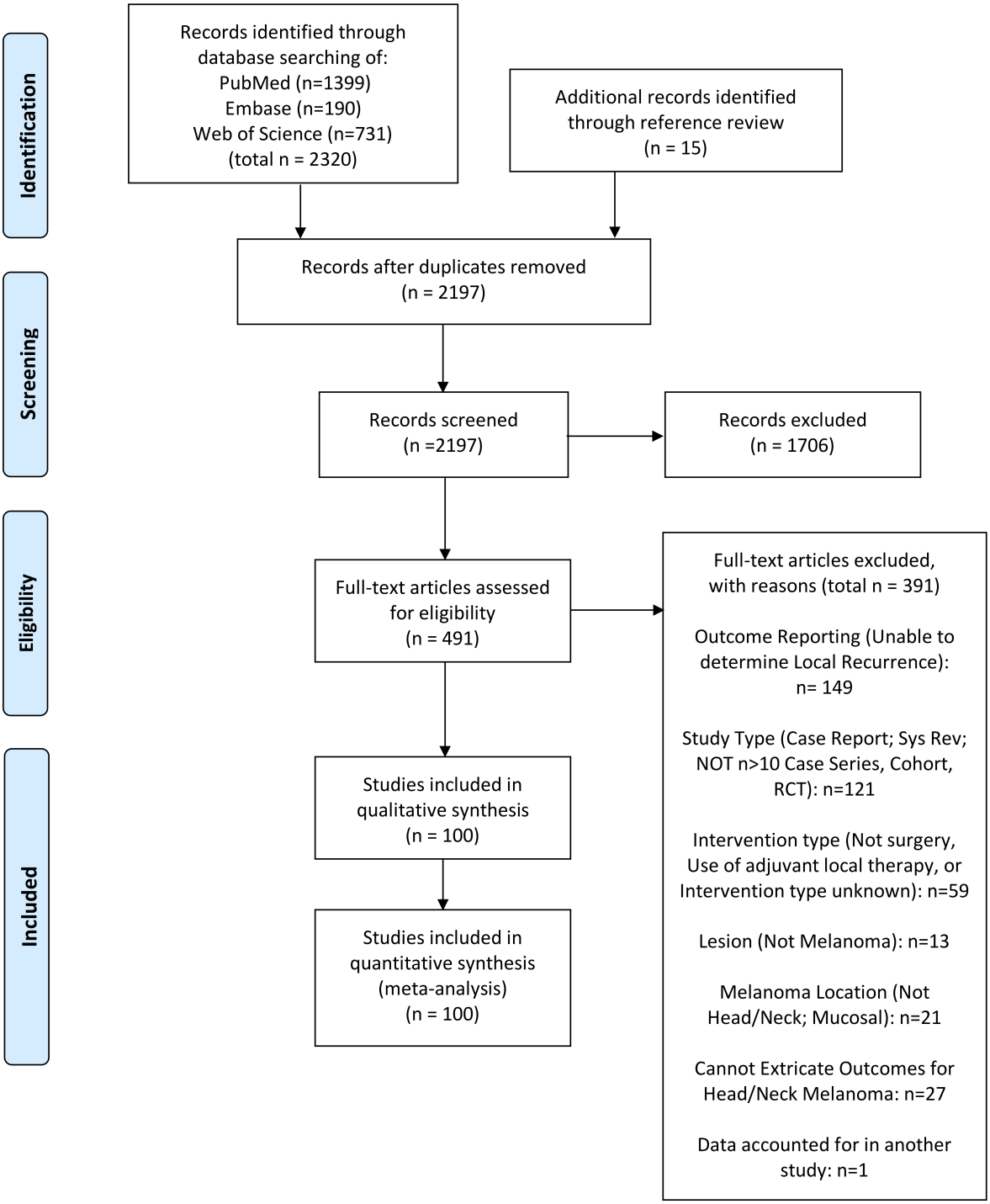
Identification
Screening
Eligibility
Included
Records identified through database searching of:
PubMed (n=1399)
Embase (n=190)
Web of Science (n=731)
(total n = 2320)
Additional records identified through reference review
(n = 15)
Records after duplicates removed
(n = 2197)
Records screened
(n =2197)
Records excluded
(n = 1706)
Full-text articles assessed for eligibility
(n = 491)
Full-text articles excluded, with reasons (total n = 391)
Outcome Reporting (Unable to determine Local Recurrence): n= 149
Study Type (Case Report; Sys Rev; NOT n>10 Case Series, Cohort, RCT): n=121
Intervention type (Not surgery, Use of adjuvant local therapy, or Intervention type unknown): n=59
Lesion (Not Melanoma): n=13
Melanoma Location (Not Head/Neck; Mucosal): n=21
Cannot Extricate Outcomes for Head/Neck Melanoma: n=27
Data accounted for in another study: n=1
Studies included in qualitative synthesis
(n = 100)
Studies included in quantitative synthesis
(meta-analysis)
(n = 100)

Figure 2
Forest plots of studies of wide local excision (WLE) [1-60]

1. Agnese DM, Maupin R, Tillman B, Pozderac RD, Magro C, Walker MJ. Head and neck melanoma in the sentinel lymph node era. *Archives of otolaryngology--head & neck surgery.* 2007;133(11):1121-1124.
2. Akhtar S, Bhat W, Magdum A, Stanley PRW. Surgical excision margins for melanoma in situ. *J Plast Reconstr Aesthet Surg.* 2014;67(3):320-323.
3. Ames FC, Sugarbaker EV, Ballantyne AJ. Analysis of survival and disease control in stage I melanoma of the head and neck. *American journal of surgery.* 1976;132(4):484-491.
4. Andersson AP, Dahlstrom KK, Drzewiecki KT. Prognosis of thin cutaneous head and neck melanoma (<1 mm). *Eur J Surg Oncol.* 1996;22(1):55-57.
5. Andersson AP, Gottlieb J, Drzewiecki KT, Hou-Jensen K, Sondergaard K. Skin melanoma of the head and neck. Prognostic factors and recurrence-free survival in 512 patients. *Cancer.* 1992;69(5):1153-1156.
6. Beenken S, Byers R, Smith JL, Goepfert H, Shallenberger R. Desmoplastic melanoma. Histologic correlation with behavior and treatment. *Archives of otolaryngology--head & neck surgery.* 1989;115(3):374-379.
7. Berdahl JP, Pockaj BA, Gray RJ, Casey WJ, Woog JJ. Optimal management and challenges in treatment of upper facial melanoma. *Annals of plastic surgery.* 2006;57(6):616-620.

8. Bogle M, Kelly P, Shenaq J, Friedman J, Evans GRD. The role of soft tissue reconstruction after melanoma resection in the head and neck. *Head Neck-J Sci Spec Head Neck.* 2001;23(1):8-15.

9. Bono A, Bartoli C, Maurichi A, Moglia D, Tragni G. Melanoma of the external ear. *Tumori.* 1997;83(5):814-817.

10. Buck D, Rawlani V, Wayne J, et al. Cosmetic outcomes following head and neck melanoma reconstruction: The patient's perspective. *Can J Plast Surg.* 2012;20(1):E10-E15.

11. Byers RM, Smith L, DeWitty R. Malignant melanoma of the skin of the nose. *American journal of otolaryngology.* 1982;3(3):202-203.

12. Carlson JA, Dickersin GR, Sober AJ, Barnhill RL. DESMOPLASTIC NEUROTROPIC MELANOMA - A CLINICOPATHOLOGICAL ANALYSIS OF 28 CASES. *Cancer.* 1995;75(2):478-494.

13. Chen JY, Hruby G, Scolyer RA, et al. Desmoplastic Neurotropic Melanoma A Clinicopathologic Analysis of 128 Cases. *Cancer.* 2008;113(10):2770-2778.

14. Chin-Lenn L, Murynka T, McKinnon JG, Arlette JP. Comparison of outcomes for malignant melanoma of the face treated using Mohs micrographic surgery and wide local excision. *Dermatologic surgery : official publication for American Society for Dermatologic Surgery [et al]*. 2013;39(11):1637-1645.

15. Cole DJ, Mackay GJ, Walker BF, Wooden WA, Murray DR, Coleman JJ, 3rd. Melanoma of the external ear. *Journal of surgical oncology.* 1992;50(2):110-114.

16. de Langen ZJ, Vermey A. Posterolateral neck dissection. *Head & neck surgery.* 1988;10(4):252-256.

17. Dika E, Fanti PA, Christman H, et al. Videodermatoscopy-assisted Mohs micrographic surgery vs. other treatments for lentigo maligna in 54 patients with a long-term follow-up. *Journal of the European Academy of Dermatology and Venereology : JEADV.* 2016;30(8):1440-1441.

18. Esmaeli B, Youssef A, Naderi A, et al. Margins of excision for cutaneous melanoma of the eyelid skin - The Collaborative Eyelid Skin Melanoma Group report. *Ophthalmic Plast Reconstr Surg.* 2003;19(2):96-101.

19. Fisher SR, Reintgen DS, Seigler HF. Juvenile malignant melanoma of the head and neck. *Laryngoscope.* 1988;98(2):184-189.

20. Frokiaer E, Kiil J, Sogaard H. The use of skin flaps in the treatment of malignant melanomas in the head and neck region. *Scandinavian journal of plastic and reconstructive surgery.* 1982;16(2):157-161.

21. Gibbs P, Robinson WA, Pearlman N, Raben D, Walsh P, Gonzalez R. Management of primary cutaneous melanoma of the head and neck: The University of Colorado experience and a review of the literature. *Journal of surgical oncology.* 2001;77(3):179-185; discussion 186-177.

22. Gomez-Rivera F, Santillan A, McMurphey AB, et al. Sentinel node biopsy in patients with cutaneous melanoma of the head and neck: recurrence and survival study. *Head & neck.* 2008;30(10):1284-1294.

23. Gyorki DE, Busam K, Panageas K, Brady MS, Coit DG. Sentinel lymph node biopsy for patients with cutaneous desmoplastic melanoma. *Annals of surgical oncology.* 2003;10(4):403-407.

24. Hafström A, Romell A, Ingvar C, Wahlberg P, Greiff L. Sentinel lymph node biopsy staging for cutaneous malignant melanoma of the head and neck. *Acta Oto-Laryngologica.* 2016;136(3):312-318.

25. Harish V, Bond JS, Scolyer RA, et al. Margins of excision and prognostic factors for cutaneous eyelid melanomas. *Journal of plastic, reconstructive & aesthetic surgery : JPRAS.* 2013;66(8):1066-1073.

26. Hudson DA, Krige JE, Grobbelaar AO, Morgan B, Grover R. Melanoma of the face: the safety of narrow excision margins. *Scandinavian journal of plastic and reconstructive surgery and hand surgery.* 1998;32(1):97-104.

27. Hudson DA, Krige JE, Strover RM, King HS. Malignant melanoma of the external ear. *British journal of plastic surgery.* 1990;43(5):608-611.

28. Jaber JJ, Clark JI, Muzaffar K, et al. Evolving treatment strategies in thin cutaneous head and neck melanoma: 1 institution's experience. *Head & neck.* 2011;33(1):7-12.

29. Jones TS, Jones EL, Gao DX, Pearlman NW, Robinson WA, McCarter M. Management of external ear melanoma: the same or something different? *Am J Surg.* 2013;206(3):307-313.

30. Kane WJ, Yugueros P, Clay RP, Woods JE. Treatment outcome for 424 primary cases of clinical stage I cutaneous malignant melanoma of the head and neck. *Head Neck-J Sci Spec Head Neck.* 1997;19(6):457-465.

31. Kilpatrick LA, Shen P, Stewart JH, Levine EA. Use of sentinel lymph node biopsy for melanoma of the head and neck. *The American surgeon.* 2007;73(8):754-758; discussion 758-759.

32. Kukar M, Gabriel E, May R, et al. Conditional Survival-Based "Abbreviated" Routine Cancer Surveillance for Pathologic Stage IB Melanoma. *The American surgeon.* 2017;83(11):1256-1262.

33. Lang NP, Stair JM, Degges RD, et al. Melanoma today does not require radical surgery. *American journal of surgery.* 1984;148(6):723-726.

34. Lent WM, Ariyan S. Flap reconstruction following wide local excision for primary malignant melanoma of the head and neck region. *Annals of plastic surgery.* 1994;33(1):23-27.

35. Lin D, Kashani-Sabet M, Singer MI. Role of the head and neck surgeon in sentinel lymph node biopsy for cutaneous head and neck melanoma. *Laryngoscope.* 2005;115(2):213-217.

36. Loree TR, Spiro RH. Cutaneous melanoma of the head and neck. *American journal of surgery.* 1989;158(4):388-391.

37. Martini L, Brandani P, Chiarugi C, Reali UM. 1ST RECURRENCE ANALYSIS OF 840 CUTANEOUS MELANOMAS - A PROPOSAL FOR A FOLLOW-UP SCHEDULE. *Tumori.* 1994;80(3):188-197.

38. McCarty MA, Lentsch EJ, Cerrati EW, Stadelmann WK. Melanoma of the ear: results of a cartilage-sparing approach to resection. *European archives of oto-rhino-laryngology : official journal of the European Federation of Oto-Rhino-Laryngological Societies (EUFOS) : affiliated with the German Society for Oto-Rhino-Laryngology - Head and Neck Surgery.* 2013;270(11):2963-2967.

39. McKenna DB, Lee RJ, Prescott RJ, Doherty VR. A retrospective observational study of primary cutaneous malignant melanoma patients treated with excision only compared

with excision biopsy followed by wider local excision. *The British journal of dermatology.* 2004;150(3):523-530.

40. Mohebati A, Ganly I, Busam KJ, et al. The role of sentinel lymph node biopsy in the management of head and neck desmoplastic melanoma. *Annals of surgical oncology.* 2012;19(13):4307-4313.

41. O'Brien CJ, Coates AS, Petersen-Schaefer K, et al. Experience with 998 cutaneous melanomas of the head and neck over 30 years. *American journal of surgery.* 1991;162(4):310-314.

42. Orr DJA, Hughes LE, Horgan K. MANAGEMENT OF MALIGNANT-MELANOMA OF THE HEAD AND NECK. *Br J Surg.* 1993;80(8):998-1000.

43. Papadopoulos T, Rasiah K, Thompson JF, Quinn MJ, Crotty KA. Melanoma of the nose. *The British journal of surgery.* 1997;84(7):986-989.

44. Parrett BM, Kashani-Sabet M, Leong SPL, Buncke N, Singer MI. The Safety of and Indications for Immediate Reconstruction of Head and Neck Melanoma Defects Our Early Experience. *Ann Plast Surg.* 2014;72:S35-S37.

45. Picon AI, Coit DG, Shaha AR, et al. Sentinel Lymph Node Biopsy for Cutaneous Head and Neck Melanoma: Mapping the Parotid Gland. *Annals of surgical oncology.* 2016;23(Suppl 5):9001-9009.

46. Plukker JT, Vermey A, Roodenburg JL, Oldhoff J. Posterolateral neck dissection: technique and results. *The British journal of surgery.* 1993;80(9):1127-1129.

47. Ravin AG, Pickett N, Johnson JL, Fisher SR, Levin LS, Seigler HF. Melanoma of the ear: treatment and survival probabilities based on 199 patients. *Annals of plastic surgery.* 2006;57(1):70-76.

48. Rawlani R, Rawlani V, Qureshi HA, Kim JY, Wayne JD. Reducing margins of wide local excision in head and neck melanoma for function and cosmesis: 5-year local recurrence-free survival. *Journal of surgical oncology.* 2015;111(7):795-799.

49. Rigual NR, Cheney RT, Iwenofu OH, et al. Idiosyncrasies of scalp melanoma. *Laryngoscope.* 2007;117(8):1354-1358.

50. Ringborg U, Afzelius LE, Lagerlof B, et al. Cutaneous malignant melanoma of the head and neck. Analysis of treatment results and prognostic factors in 581 patients: a report from the Swedish Melanoma Study Group. *Cancer.* 1993;71(3):751-758.

51. Saltman BE, Ganly I, Patel SG, et al. Prognostic implication of sentinel lymph node biopsy in cutaneous head and neck melanoma. *Head & neck.* 2010;32(12):1686-1692.

52. Sekido M, Yamamoto Y, Tsutsumida A, et al. Reconstructive considerations after resection of malignant melanoma in the head and neck. *Scandinavian journal of plastic and reconstructive surgery and hand surgery.* 2005;39(4):222-226.

53. Shpitzer T, Gutman H, Barnea Y, et al. Sentinel node-guided evaluation of drainage patterns for melanoma of the helix of the ear. *Melanoma research.* 2007;17(6):365-369.

54. Sullivan SR, Liu DZ, Mathes DW, Isik FF. Head and neck malignant melanoma: local recurrence rate following wide local excision and immediate reconstruction. *Annals of plastic surgery.* 2012;68(1):33-36.

55. Urist MM, Balch CM, Soong SJ, et al. Head and neck melanoma in 534 clinical Stage I patients. A prognostic factors analysis and results of surgical treatment. *Annals of surgery.* 1984;200(6):769-775.

56. Vaziri M, Buffam FV, Martinka M, Oryschak A, Dhaliwal H, White VA. Clinicopathologic features and behavior of cutaneous eyelid melanoma. *Ophthalmology.* 2002;109(5):901-908.

57. Vreeburg GC, Schouwenburg PF, Hilgers FJ, de Kraker NW, Hart AA. Cutaneous melanoma of the head and neck. *European journal of surgical oncology : the journal of the European Society of Surgical Oncology and the British Association of Surgical Oncology.* 1988;14(2):165-170.

58. Wanebo HJ, Cooper PH, Young DV, Harpole DH, Kaiser DL. Prognostic factors in head and neck melanoma. Effect of lesion location. *Cancer.* 1988;62(4):831-837.

59. Davidsson A, Hellquist HB, Villman K, Westman G. MALIGNANT-MELANOMA OF THE EAR. *J Laryngol Otol.* 1993;107(9):798-802.

60. Pockaj BA, Jaroszewski DE, DiCaudo DJ, et al. Changing surgical therapy for melanoma of the external ear. *Ann Surg Oncol.* 2003;10(6):689-696.

Studies: WLE	Estimate (95% C.I.)	Ev/Trt
Ames et al. 1976	0.0422 (0.0160, 0.0789)	7/166
Byers et al. 1982	0.0588 (0.0000, 0.2354)	1/17
Frokiaer et al. 1982	0.0728 (0.0361, 0.1204)	11/151
Lang et al. 1984	0.0274 (0.0004, 0.0808)	2/73
Urist et al. 1984	0.0412 (0.0258, 0.0599)	22/534
de Langen et al. 1988	0.0427 (0.0000, 0.2739)	0/10
Fisher et al. 1988	0.2000 (0.0298, 0.4460)	3/15
Vreeburg et al. 1988	0.0429 (0.0054, 0.1058)	3/70
Wanebo et al. 1988	0.1446 (0.0761, 0.2294)	12/83
Beenken et al. 1989	0.4615 (0.1949, 0.7391)	6/13
Loree et al. 1989	0.1696 (0.1283, 0.2151)	49/289
Hudson et al. 1990	0.2500 (0.0393, 0.5392)	3/12
O'Brien et al. 1991	0.1303 (0.1101, 0.1519)	130/998
Andersson et al. 1992	0.0742 (0.0530, 0.0986)	38/512
Cole et al. 1992	0.0645 (0.0012, 0.1847)	2/31
Orr et al. 1993	0.1136 (0.0546, 0.1894)	10/88
Plukker et al. 1993	0.0241 (0.0000, 0.1567)	0/19
Ringborg et al. 1993	0.0826 (0.0615, 0.1065)	48/581
Davidsson et al. 1993	0.2857 (0.0741, 0.5544)	4/14
Lent et al. 1994	0.0133 (0.0000, 0.0867)	0/36
Martini et al. 1994	0.0299 (0.0064, 0.0669)	4/134
Carlson et al. 1995	0.2857 (0.1092, 0.5004)	6/21
Andersson et al. 1996	0.0270 (0.0058, 0.0606)	4/148
Bono et al. 1997	0.0230 (0.0000, 0.1496)	0/20
Kane et al. 1997	0.0519 (0.0326, 0.0752)	22/424
Papadopoulos et al. 1997	0.2353 (0.1056, 0.3944)	8/34
Hudson et al. 1998	0.0700 (0.0269, 0.1296)	7/100
Bogle et al. 2001	0.1143 (0.0261, 0.2445)	4/35
Gibbs et al. 2001	0.0655 (0.0324, 0.1085)	11/168
Vaziri et al. 2002	0.3684 (0.1629, 0.5997)	7/19
Esmaeli et al. 2003	0.2500 (0.1317, 0.3898)	11/44
Gyorki et al. 2003	0.0714 (0.0000, 0.2816)	1/14
Pockaj et al. 2003	0.1385 (0.0637, 0.2344)	9/65
McKenna et al. 2004	0.0638 (0.0385, 0.0946)	19/298
Lin et al. 2005	0.1154 (0.0526, 0.1970)	9/78
Sekido et al. 2005	0.0211 (0.0000, 0.1372)	0/22
Berdahl et al. 2006	0.1250 (0.0374, 0.2483)	5/40
Ravin et al. 2006	0.1055 (0.0663, 0.1524)	21/199
Agnese et al. 2007	0.0611 (0.0255, 0.1095)	8/131
Kilpatrick et al. 2007	0.0685 (0.0198, 0.1399)	5/73
Rigual et al. 2007	0.0455 (0.0000, 0.1849)	1/22
Shpitzer et al. 2007	0.0299 (0.0000, 0.1935)	0/15
Chen et al. 2008	0.1282 (0.0384, 0.2543)	5/39
Gomez−Rivera et al. 2008	0.0796 (0.0358, 0.1377)	9/113
Saltman et al. 2010	0.0556 (0.0294, 0.0890)	13/234
Jaber et al. 2011	0.0204 (0.0000, 0.0855)	1/49
Buck et al. 2012	0.0526 (0.0068, 0.1291)	3/57
Mohebati et al. 2012	0.2424 (0.1091, 0.4051)	8/33
Sullivan et al. 2012	0.0278 (0.0004, 0.0819)	2/72
Chin−Lenn et al. 2013	0.0769 (0.0296, 0.1420)	7/91
Harish et al. 2013	0.2143 (0.1155, 0.3325)	12/56
Jones et al. 2013	0.1200 (0.0421, 0.2269)	6/50
McCarty et al. 2013	0.0254 (0.0000, 0.1645)	0/18
Akhtar et al. 2014	0.0482 (0.0105, 0.1069)	4/83
Parrett et al. 2014	0.0316 (0.0040, 0.0785)	3/95
Dika et al. 2015	0.2400 (0.0895, 0.4295)	6/25
Rawlani et al. 2015	0.0886 (0.0343, 0.1628)	7/79
Hafstrom et al. 2016	0.0616 (0.0275, 0.1073)	9/146
Picon et al. 2016	0.0139 (0.0000, 0.0587)	1/72
Kukar et al. 2017	0.0427 (0.0000, 0.2739)	0/10
Overall (I^2= 72.08%, P< 1e−04)	**0.0781 (0.0640, 0.0934)**	**609/7138**

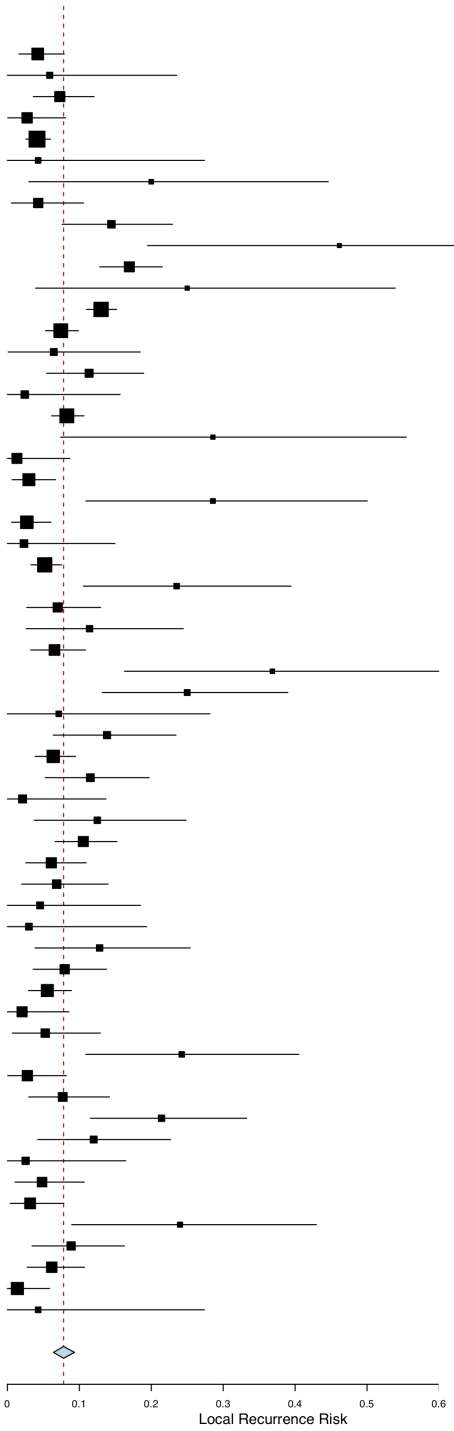

Figure 3
Forest plots of studies of Mohs micrographic surgery (MMS), including studies with, without, and with and without IHC [1-22]

1. Bienert TN, Trotter MJ, Arlette JP. Treatment of cutaneous melanoma of the face by Mohs micrographic surgery. *J Cutan Med Surg.* 2003;7(1):25-30.
2. Chin-Lenn L, Murynka T, McKinnon JG, Arlette JP. Comparison of outcomes for malignant melanoma of the face treated using Mohs micrographic surgery and wide local excision. *Dermatologic surgery : official publication for American Society for Dermatologic Surgery [et al]*. 2013;39(11):1637-1645.
3. Dika E, Fanti PA, Christman H, et al. Videodermatoscopy-assisted Mohs micrographic surgery vs. other treatments for lentigo maligna in 54 patients with a long-term follow-up. *Journal of the European Academy of Dermatology and Venereology : JEADV.* 2016;30(8):1440-1441.
4. Jones TS, Jones EL, Gao DX, Pearlman NW, Robinson WA, McCarter M. Management of external ear melanoma: the same or something different? *Am J Surg.* 2013;206(3):307-313.
5. Mohs FE. Fixed-tissue micrographic surgery for melanoma of the ear. *Archives of otolaryngology--head & neck surgery.* 1988;114(6):625-631.
6. Mohs FE, Snow SN, Larson PO. Mohs micrographic surgery fixed-tissue technique for melanoma of the nose. *The Journal of dermatologic surgery and oncology.* 1990;16(12):1111-1120.
7. Nosrati A, Berliner JG, Goel S, et al. Outcomes of Melanoma In Situ Treated With Mohs Micrographic Surgery Compared With Wide Local Excision. *JAMA dermatology.* 2017;153(5):436-441.

8. Snow SN, Mohs FE, Oriba HA, Dudley CM, Leverson G, Hetzer M. Cutaneous malignant melanoma treated by Mohs surgery. Review of the treatment results of 179 cases from the Mohs Melanoma Registry. *Dermatologic surgery : official publication for American Society for Dermatologic Surgery [et al]*. 1997;23(11):1055-1060.

9. Temple CL, Arlette JP. Mohs micrographic surgery in the treatment of lentigo maligna and melanoma. *Journal of surgical oncology.* 2006;94(4):287-292.

10. Walling HW, Scupham RK, Bean AK, Ceilley RI. Staged excision versus Mohs micrographic surgery for lentigo maligna and lentigo maligna melanoma. *J Am Acad Dermatol.* 2007;57(4):659-664.

11. Bhardwaj SS, Tope WD, Lee PK. Mohs micrographic surgery for lentigo maligna and lentigo maligna melanoma using Mel-5 immunostaining: University of Minnesota experience. *Dermatologic surgery : official publication for American Society for Dermatologic Surgery [et al]*. 2006;32(5):690-696; discussion 696-697.

12. Etzkorn JR, Sobanko JF, Elenitsas R, et al. Low recurrence rates for in situ and invasive melanomas using Mohs micrographic surgery with melanoma antigen recognized by T cells 1 (MART-1) immunostaining: Tissue processing methodology to optimize pathologic staging and margin assessment. *J Am Acad Dermatol.* 2015;72(5):840-850.

13. Felton S, Taylor RS, Srivastava D. Excision Margins for Melanoma In Situ on the Head and Neck. *Dermatologic surgery : official publication for American Society for Dermatologic Surgery [et al]*. 2016;42(3):327-334.

14. Foxton GC, Elliott TG, Litterick KA. Treating melanoma in situ and lentigo maligna with Mohs micrographic surgery in Australia. *The Australasian journal of dermatology.* 2019;60(1):33-37.

15. Newman J, Beal M, Schram SE, Lee PK. Mohs micrographic surgery for lentigo maligna and lentigo maligna melanoma using Mel-5 immunostaining: an update from the University of Minnesota. *Dermatologic surgery : official publication for American Society for Dermatologic Surgery [et al]*. 2013;39(12):1794-1799.

16. Valentin-Nogueras SM, Brodland DG, Zitelli JA, Gonzalez-Sepulveda L, Nazario CM. Mohs Micrographic Surgery Using MART-1 Immunostain in the Treatment of Invasive Melanoma and Melanoma In Situ. *Dermatologic surgery : official publication for American Society for Dermatologic Surgery [et al]*. 2016;42(6):733-744.

17. Zalla MJ, Lim KK, Dicaudo DJ, Gagnot MM. Mohs micrographic excision of melanoma using immunostains. *Dermatologic surgery : official publication for American Society for Dermatologic Surgery [et al]*. 2000;26(8):771-784.

18. Bricca GM, Brodland DG, Ren DX, Zitelli JA. Cutaneous head and neck melanoma treated with Mohs micrographic surgery. *J Am Acad Dermatol.* 2005;52(1):92-100.

19. Hou JL, Reed KB, Knudson RM, et al. Five-Year Outcomes of Wide Excision and Mohs Micrographic Surgery for Primary Lentigo Maligna in an Academic Practice Cohort. *Dermatol Surg.* 2015;41(2):211-218.

20. Kunishige JH, Brodland DG, Zitelli JA. Surgical margins for melanoma in situ. *Journal of the American Academy of Dermatology.* 2012;66(3):438-444.

21. Pockaj BA, Jaroszewski DE, DiCaudo DJ, et al. Changing surgical therapy for melanoma of the external ear. *Ann Surg Oncol.* 2003;10(6):689-696.

22. Zitelli JA, Brown C, Hanusa BH. Mohs micrographic surgery for the treatment of primary cutaneous melanoma. *J Am Acad Dermatol.* 1997;37(2):236-245.

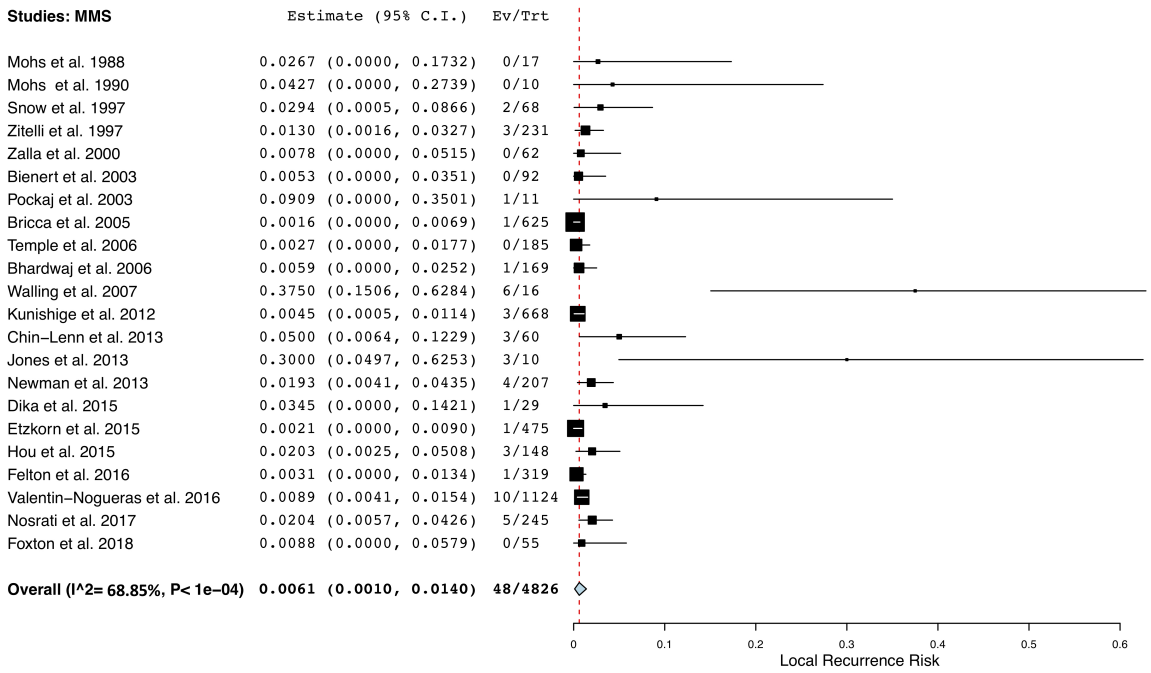
Studies: MMS
Estimate (95% C.I.)
Ev/Trt
Mohs et al. 1988 0.0267 (0.0000, 0.1732) 0/17
Mohs et al. 1990 0.0427 (0.0000, 0.2739) 0/10
Snow et al. 1997 0.0294 (0.0005, 0.0866) 2/68
Zitelli et al. 1997 0.0130 (0.0016, 0.0327) 3/231
Zalla et al. 2000 0.0078 (0.0000, 0.0515) 0/62
Bienert et al. 2003 0.0053 (0.0000, 0.0351) 0/92
Pockaj et al. 2003 0.0909 (0.0000, 0.3501) 1/11
Bricca et al. 2005 0.0016 (0.0000, 0.0069) 1/625
Temple et al. 2006 0.0027 (0.0000, 0.0177) 0/185
Bhardwaj et al. 2006 0.0059 (0.0000, 0.0252) 1/169
Walling et al. 2007 0.3750 (0.1506, 0.6284) 6/16
Kunishige et al. 2012 0.0045 (0.0005, 0.0114) 3/668
Chin−Lenn et al. 2013 0.0500 (0.0064, 0.1229) 3/60
Jones et al. 2013 0.3000 (0.0497, 0.6253) 3/10
Newman et al. 2013 0.0193 (0.0041, 0.0435) 4/207
Dika et al. 2015 0.0345 (0.0000, 0.1421) 1/29
Etzkorn et al. 2015 0.0021 (0.0000, 0.0090) 1/475
Hou et al. 2015 0.0203 (0.0025, 0.0508) 3/148
Felton et al. 2016 0.0031 (0.0000, 0.0134) 1/319
Valentin−Nogueras et al. 2016 0.0089 (0.0041, 0.0154) 10/1124
Nosrati et al. 2017 0.0204 (0.0057, 0.0426) 5/245
Foxton et al. 2018 0.0088 (0.0000, 0.0579) 0/55
Overall (I^2= 68.85%, P< 1e−04) 0.0061 (0.0010, 0.0140) 48/4826
0
0.1
0.2
0.3
0.4
0.5
0.6
Local Recurrence Risk

Figure 4:
Forest plots of studies of staged excision (SE), including studies with complete and partial peripheral margin assessment[1-23]

1. Kassi K, Vanwijck R, Kanga JM. The "collerette" technique for skin excision and biopsy: an efficient method for managing lentigo maligna of the head and neck. *International journal of dermatology.* 2014;53(7):899-903.
2. Glazer ES, Porubsky CF, Francis JD, et al. Treatment of Head and Neck Melanoma In Situ With Staged Contoured Marginal Excisions. *Annals of plastic surgery.* 2017;78(6):663-667.
3. Moller MG, Pappas-Politis E, Zager JS, et al. Surgical Management of Melanoma-In-Situ Using a Staged Marginal and Central Excision Technique. *Ann Surg Oncol.* 2009;16(6):1526-1536.
4. Bosbous MW, Dzwierzynski WW, Neuburg M. Staged Excision of Lentigo Maligna and Lentigo Maligna Melanoma: A 10-Year Experience. *Plast Reconstr Surg.* 2009;124(6):1947-1955.
5. Clayton BD, Leshin B, Hitchcock MG, Marks M, White WL. Utility of rush paraffin-embedded tangential sections in the management of cutaneous neoplasms. *Dermatologic surgery : official publication for American Society for Dermatologic Surgery [et al]*. 2000;26(7):671-678.
6. Cohen LM, McCall MW, Hodge SJ, Freedman JD, Callen JP, Zax RH. SUCCESSFUL TREATMENT OF LENTIGO-MALIGNA AND LENTIGO-MALIGNA MELANOMA WITH MOBS MICROGRAPHIC SURGERY AIDED BY RUSH PERMANENT SECTIONS. *Cancer.* 1994;73(12):2964-2970.

7. Jahn V, Breuninger H, Garbe C, Maassen MM, Moehrle M. Melanoma of the nose: prognostic factors, three-dimensional histology, and surgical strategies. *Laryngoscope.* 2006;116(7):1204-1211.

8. Lee MR, Ryman WJ. Treatment of lentigo maligna with total circumferential margin control using vertical and horizontal permanent sections: a retrospective study. *The Australasian journal of dermatology.* 2008;49(4):196-201.

9. Mahoney EJ, Dolan RW, Choi EE, Olbricht SM. Surgical reconstruction of lentigo maligna defects. *Arch Facial Plast Surg.* 2005;7(5):342-346.

10. Then SY, Malhotra R, Barlow R, et al. Early cure rates with narrow-margin slow-Mohs surgery for periocular malignant melanoma. *Dermatologic surgery : official publication for American Society for Dermatologic Surgery [et al]*. 2009;35(1):17-23.

11. Agarwal-Antal N, Bowen GM, Gerwels JW. Histologic evaluation of lentigo maligna with permanent sections: Implications regarding current guidelines. *J Am Acad Dermatol.* 2002;47(5):743-748.

12. Abdelmalek M, Loosemore MP, Hurt MA, Hruza G. Geometric staged excision for the treatment of lentigo maligna and lentigo maligna melanoma: a long-term experience with literature review. *Archives of dermatology.* 2012;148(5):599-604.

13. Mahoney MH, Joseph M, Temple CL. The perimeter technique for lentigo maligna: an alternative to Mohs micrographic surgery. *Journal of surgical oncology.* 2005;91(2):120-125.

14. Shumaker PR, Kelley B, Swann MH, Greenway HT, Jr. Modified Mohs micrographic surgery for periocular melanoma and melanoma in situ: long-term experience at Scripps

Clinic. *Dermatologic surgery : official publication for American Society for Dermatologic Surgery [et al]*. 2009;35(8):1263-1270.

15. Champin J, Perrot JL, Cinotti E, et al. In vivo reflectance confocal microscopy to optimize the spaghetti technique for defining surgical margins of lentigo maligna. *Dermatologic surgery : official publication for American Society for Dermatologic Surgery [et al]*. 2014;40(3):247-256.

16. Gaudy-Marqueste C, Perchenet AS, Tasei AM, et al. The "spaghetti technique": an alternative to Mohs surgery or staged surgery for problematic lentiginous melanoma (lentigo maligna and acral lentiginous melanoma). *Journal of the American Academy of Dermatology.* 2011;64(1):113-118.

17. Demirci H, Johnson TM, Frueh BR, Musch DC, Fullen DR, Nelson CC. Management of periocular cutaneous melanoma with a staged excision technique and permanent sections the square procedure. *Ophthalmology.* 2008;115(12):2295-2300.e2293.

18. Jejurikar SS, Borschel GH, Johnson TM, Lowe L, Brown DL. Immediate, optimal reconstruction of facial lentigo maligna and melanoma following total peripheral margin control. *Plastic and reconstructive surgery.* 2007;120(5):1249-1255.

19. Moyer JS, Rudy S, Boonstra PS, et al. Efficacy of Staged Excision With Permanent Section Margin Control for Cutaneous Head and Neck Melanoma. *JAMA dermatology.* 2017;153(3):282-288.

20. Patel AN, Perkins W, Leach IH, Varma S. Johnson square procedure for lentigo maligna and lentigo maligna melanoma. *Clinical and experimental dermatology.* 2014;39(5):570-576.

21. Hill DC, Gramp AA. Surgical treatment of lentigo maligna and lentigo maligna melanoma. *The Australasian journal of dermatology.* 1999;40(1):25-30.

22. Huilgol SC, Selva D, Chen C, et al. Surgical margins for lentigo maligna and lentigo maligna melanoma - The technique of mapped serial excision. *Arch Dermatol.* 2004;140(9):1087-+.

23. Walling HW, Scupham RK, Bean AK, Ceilley RI. Staged excision versus Mohs micrographic surgery for lentigo maligna and lentigo maligna melanoma. *J Am Acad Dermatol.* 2007;57(4):659-664.

Studies: SE	Estimate (95% C.I.)	Ev/Trt
Cohen et al. 1994	0.0117 (0.0000, 0.0767)	0/41
Hill et al. 1999	0.0152 (0.0000, 0.0639)	1/66
Clayton et al. 2000	0.0104 (0.0000, 0.0442)	1/96
Agarwal−Antal et al. 2002	0.0071 (0.0000, 0.0465)	0/69
Huilgol et al. 2004	0.0258 (0.0055, 0.0579)	4/155
Mahoney et al. 2005	0.0427 (0.0000, 0.2739)	0/10
Mahoney et al. 2005	0.0435 (0.0000, 0.1773)	1/23
Jahn et al. 2006	0.0187 (0.0000, 0.1220)	0/25
Jejurikar et al. 2007	0.0095 (0.0000, 0.0622)	0/51
Walling et al. 2007	0.1111 (0.0151, 0.2626)	3/27
Lee et al. 2008	0.1111 (0.0151, 0.2626)	3/27
Demirci et al. 2008	0.0250 (0.0000, 0.1042)	1/40
Moller et al. 2009	0.0099 (0.0000, 0.0647)	0/49
Bosbous et al. 2009	0.0172 (0.0000, 0.0725)	1/58
Then et al. 2009	0.1429 (0.0033, 0.3841)	2/14
Shumaker et al. 2009	0.1724 (0.0530, 0.3346)	5/29
Gaudy−Marqueste et al. 2011	0.0282 (0.0000, 0.1828)	0/16
Abdelmalek et al. 2012	0.0202 (0.0043, 0.0455)	4/198
Kassi et al. 2014	0.0323 (0.0000, 0.1333)	1/31
Champin et al. 2014	0.0174 (0.0000, 0.1136)	0/27
Patel et al. 2014	0.0476 (0.0000, 0.1932)	1/21
Glazer et al. 2017	0.0236 (0.0029, 0.0590)	3/127
Moyer et al. 2017	0.0204 (0.0118, 0.0312)	17/834
Overall (I^2=19.96 % , P=0.1933)	**0.0184 (0.0097 , 0.0290)**	**48/2034**

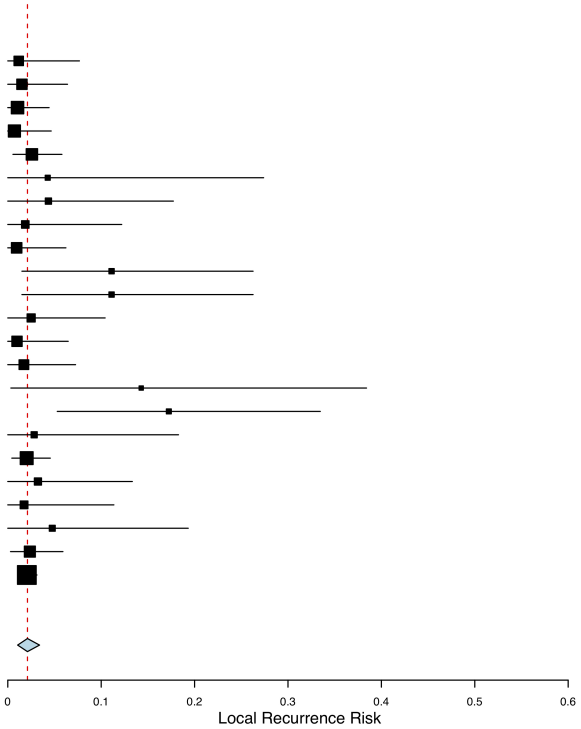

Capsule summary

- Prospective trials have not compared local recurrence rates for different excision techniques for cutaneous head and neck melanomas.
- Systematic review of retrospective data shows lower local recurrence rates of cutaneous head and neck melanomas after Mohs micrographic surgery or staged excision versus wide local excision.